Trigger Warning!

(Sexist joke ahead)

In the hospital the relatives gathered in the waiting room, where their family member lay gravely ill. Finally, the doctor came in looking tired and somber.

“I'm afraid I am the bearer of bad news,” he said as he surveyed the worried faces. "The only hope left for your loved one at this time is a brain transplant.

It's an experimental procedure, semi-risky, and you will have to pay for the brain yourselves.”

The family members sat silent as they absorbed the news.
After a length of time, someone asked, "Well, how much does a brain cost?"

The Doctor quickly responded, “$5000 for a male brain, and $200 for a female brain.”

The moment turned awkward. Men in the room tried not to smile, avoiding eye contact with the women, but some actually smirked.

A man, unable to control his curiosity, blurted out the question everyone wanted to ask, “Why is the male brain so much more?”

The doctor smiled at the childish innocence and then to the entire group said, “It's just standard pricing procedure.

We have to mark down the price of the female brains, because they've been used."

Unit 3B:
Biological Bases of Behavior:
The Brain

Unit Overview

- The Tools of Discovery: Having Our Head Examined
- Older Brain Structures
- The Cerebral Cortex
- Our Divided Brain
- Right-Left Differences in the Intact Brain
- The Brain and Consciousness

Click on the any of the above hyperlinks to go to that section in the presentation.

The Tools of Discovery: Having Our Head Examined

Introduction

- Lesion

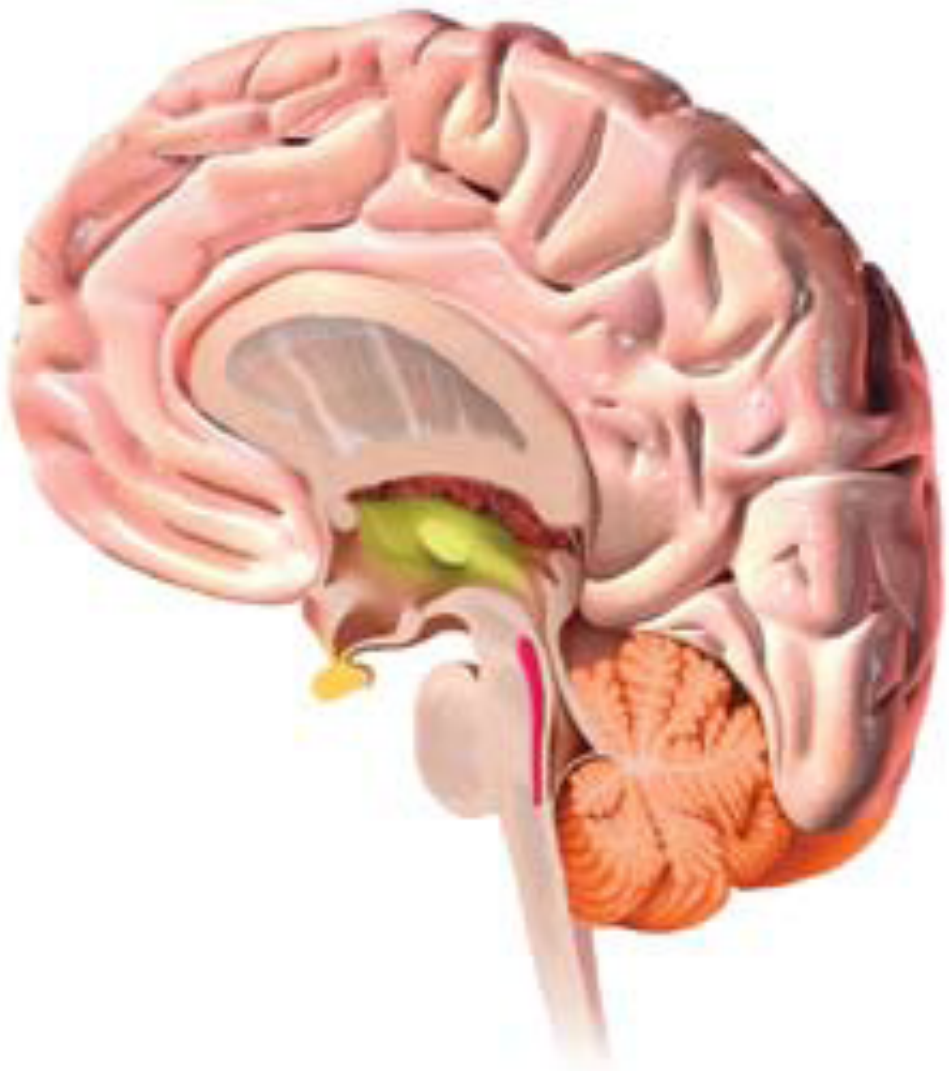

- **What Are Brain Lesions?**
- A lesion is an area of tissue that has been damaged through injury or disease. There are many types of brain lesions. They can range from small to large, from few to many, from relatively harmless to life threatening.

Recording the Brain's Electrical Activity

- Electroencephalogram (EEG)

An amplified recording of the electrical waves sweeping across the brain's surface, measured by electrodes placed on the scalp.

Neuroimaging Techniques

- CT (Computed Tomography) scan
- PET (Positron Emission Tomography) scan
- MRI (Magnetic Resonance Imaging)
- fMRI (Functional MRI)

- CT (computed tomography) Scan
  - a series of x-ray photographs taken from different angles and combined by computer into a composite representation of a slice through the body; also called CAT scan

- PET (positron emission tomography) Scan
  - a visual display of brain activity that detects where a radioactive form of glucose goes while the brain performs a given task

PET Scan

PET (positron emission tomography) Scan is a visual display of brain activity that detects a radioactive form of glucose while the brain performs a given task.

Courtesy of National Brookhaven National Laboratories

PET Scan

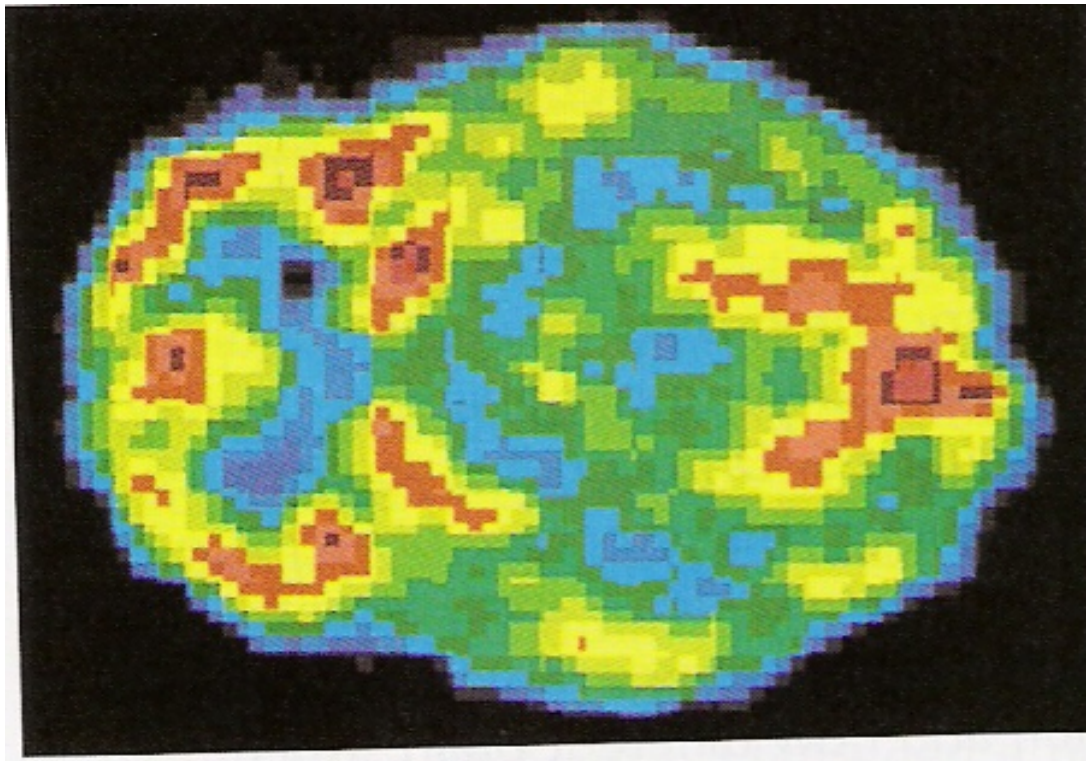

PET Scan of a Normal Brain

- MRI (magnetic resonance imaging)
  - a technique that uses magnetic fields and radio waves to produce computer-generated images that distinguish among different types of soft tissue; allows us to see structures within the brain
- Stimulation
  - Electrical stimulation of the brain involves sending a weak electric current into a brain structure to stimulate it. (It is not painful because the brain has no pain receptors

MRI Scan

MRI (magnetic resonance imaging) uses magnetic fields and radio waves to produce computer-generated images that distinguish among different types of brain tissue. Top images show ventricular enlargement in a schizophrenic patient. Bottom image shows brain regions when a participants lies.

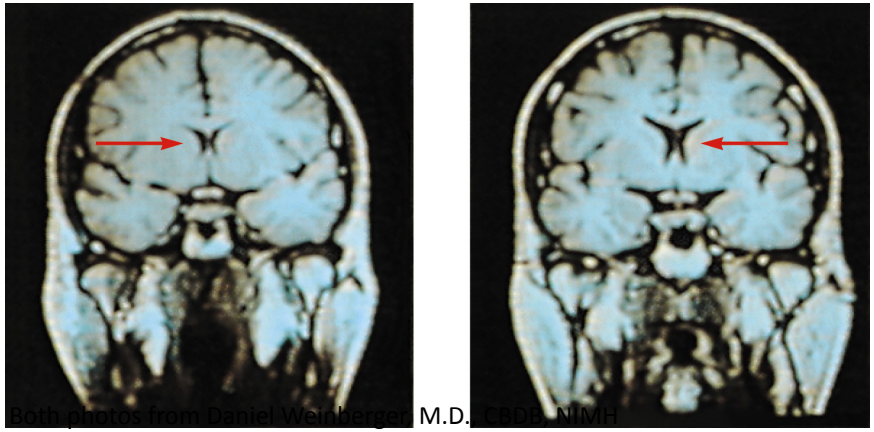

Both photos from Daniel Weinberger, M.D., CBDB, NIMH

James Salzano/ Salzano Photo

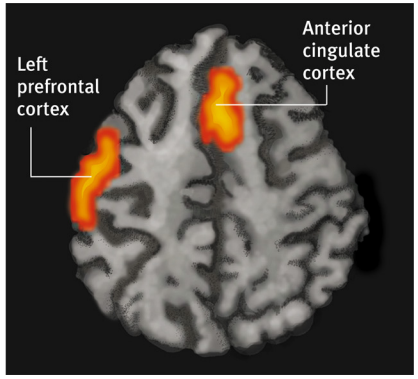

Lucy Reading/ Lucy Illustrations

Older Brain Structures

- Brainstem
  - the oldest part and central core of the brain, beginning where the spinal cord swells as it enters the skull
  - responsible for automatic survival functions

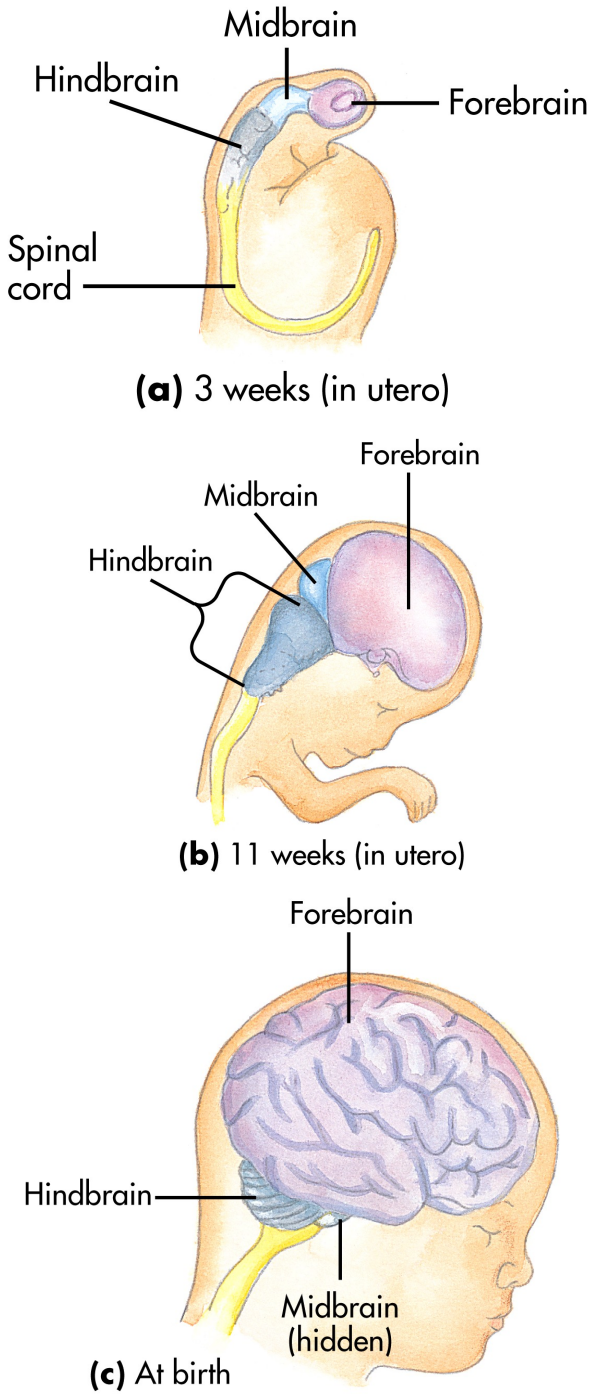

Developing Brain

- Neural tube—beginning of nervous system develops at 2 weeks after conception
- Neurogenesis—development of new neurons

Older Brain Structures

The Brainstem is the oldest part of the brain, beginning where the spinal cord swells and enters the skull. It is responsible for automatic survival functions.

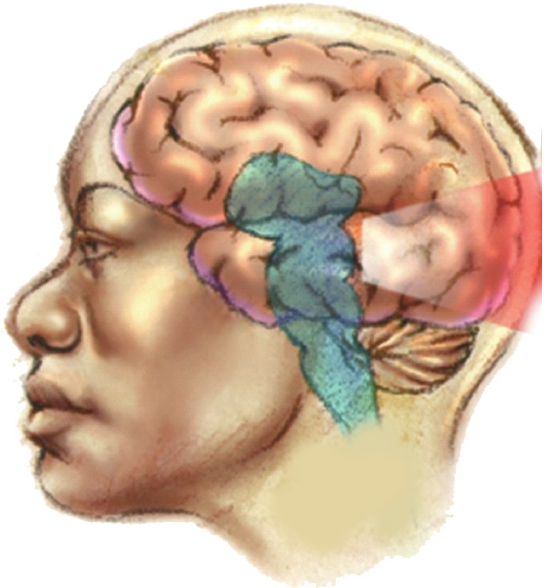

The Brainstem

- Brainstem
  - Medulla
  - Pons
  - Reticular formation

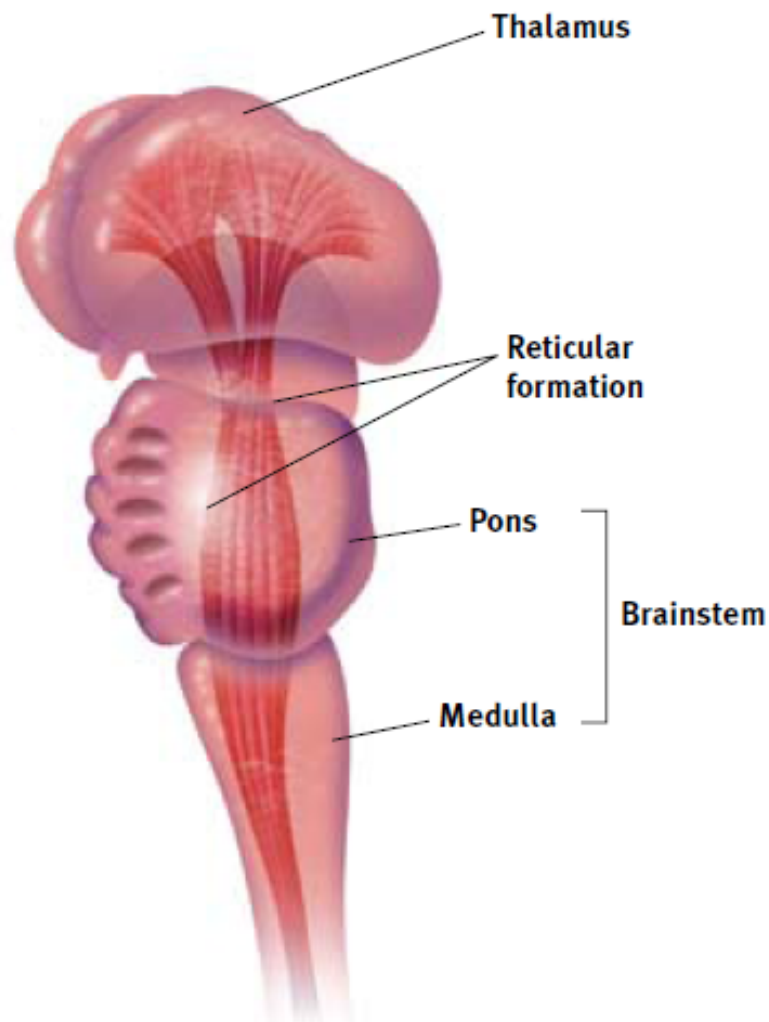

Brain Stem

The Medulla is the base of the brainstem that controls heartbeat and breathing.

Reticular Formation is a nerve network in the brainstem that plays an important role in controlling arousal.

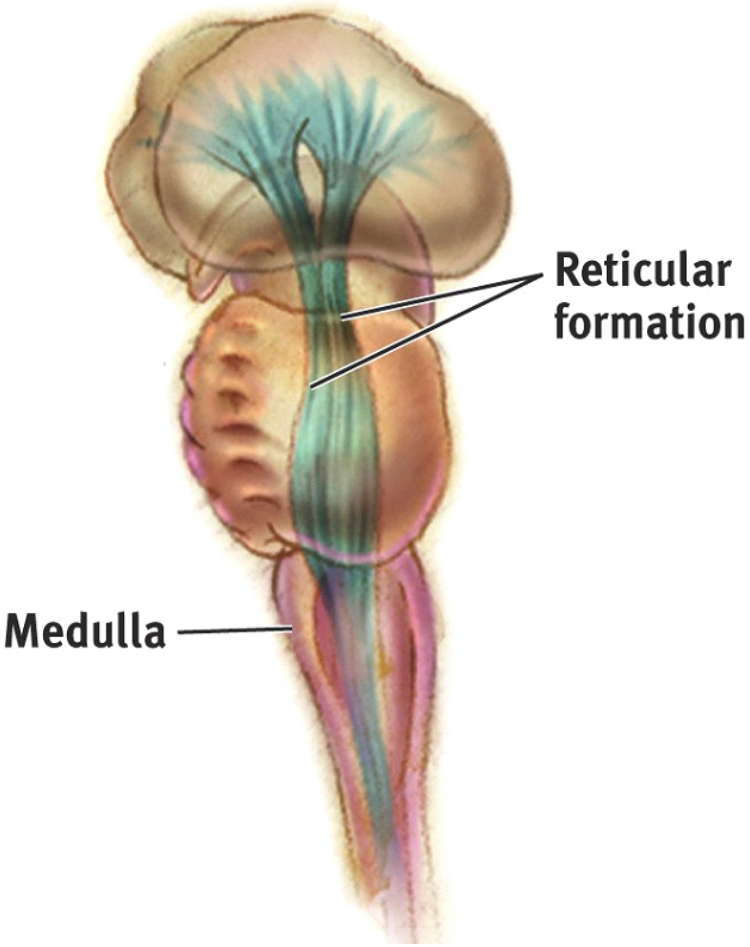

The Thalamus

- Thalamus
  - All the senses EXCEPT smell

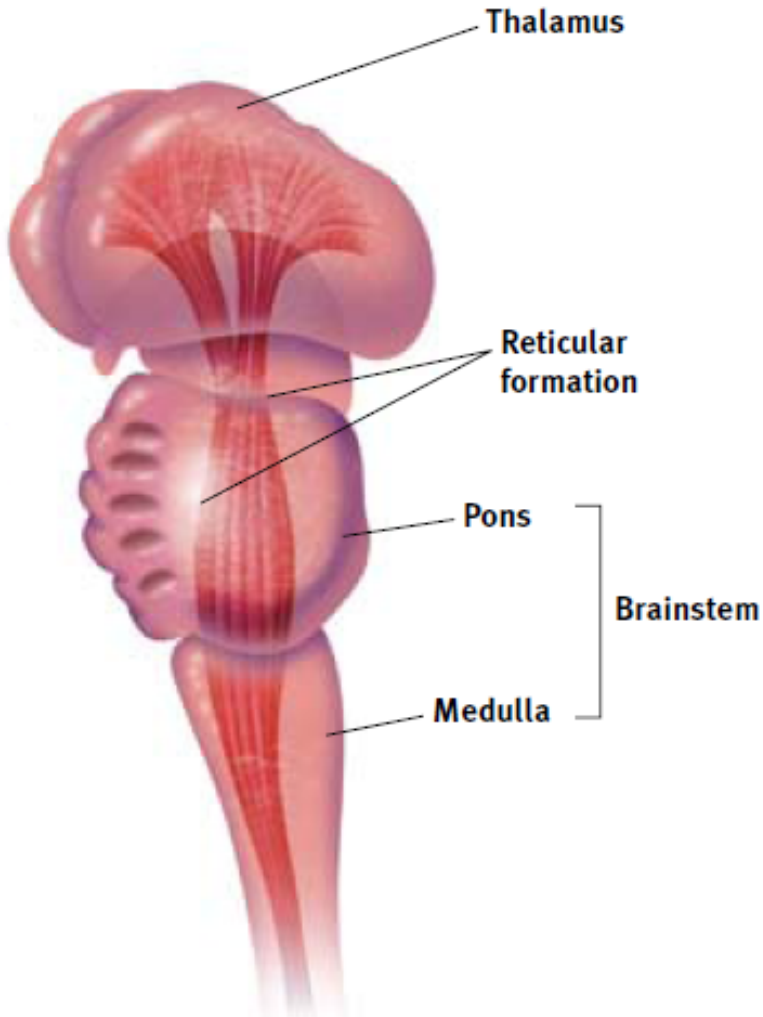

Brain Stem

The Thalamus is the brain's sensory switchboard, located on top of the brainstem. It directs messages to the sensory areas in the cortex and transmits replies to the cerebellum and medulla.

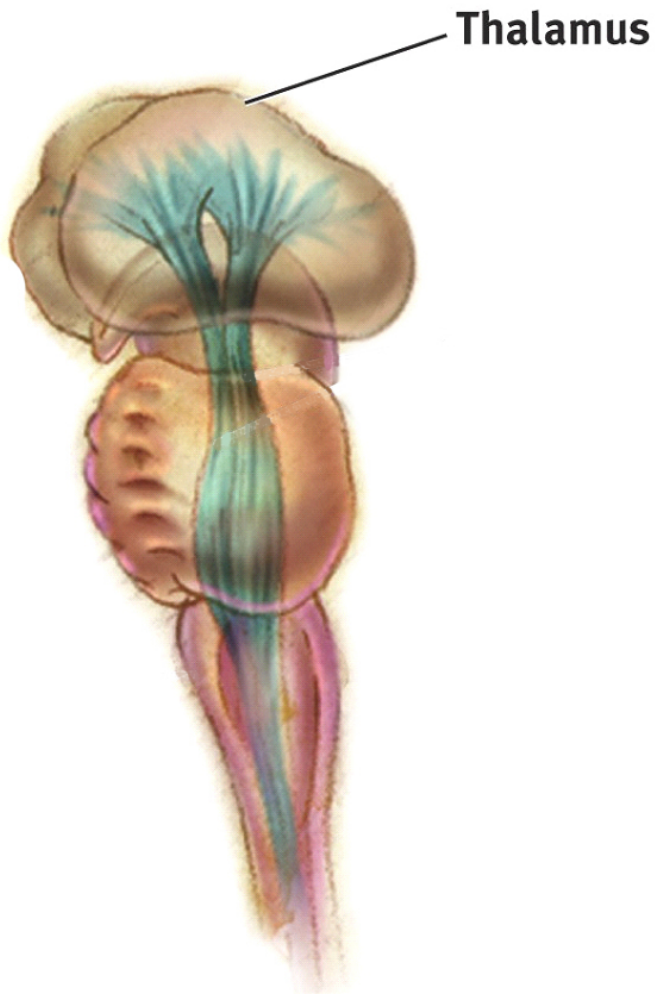

The Cerebellum

- Cerebellum
  - "Little brain"

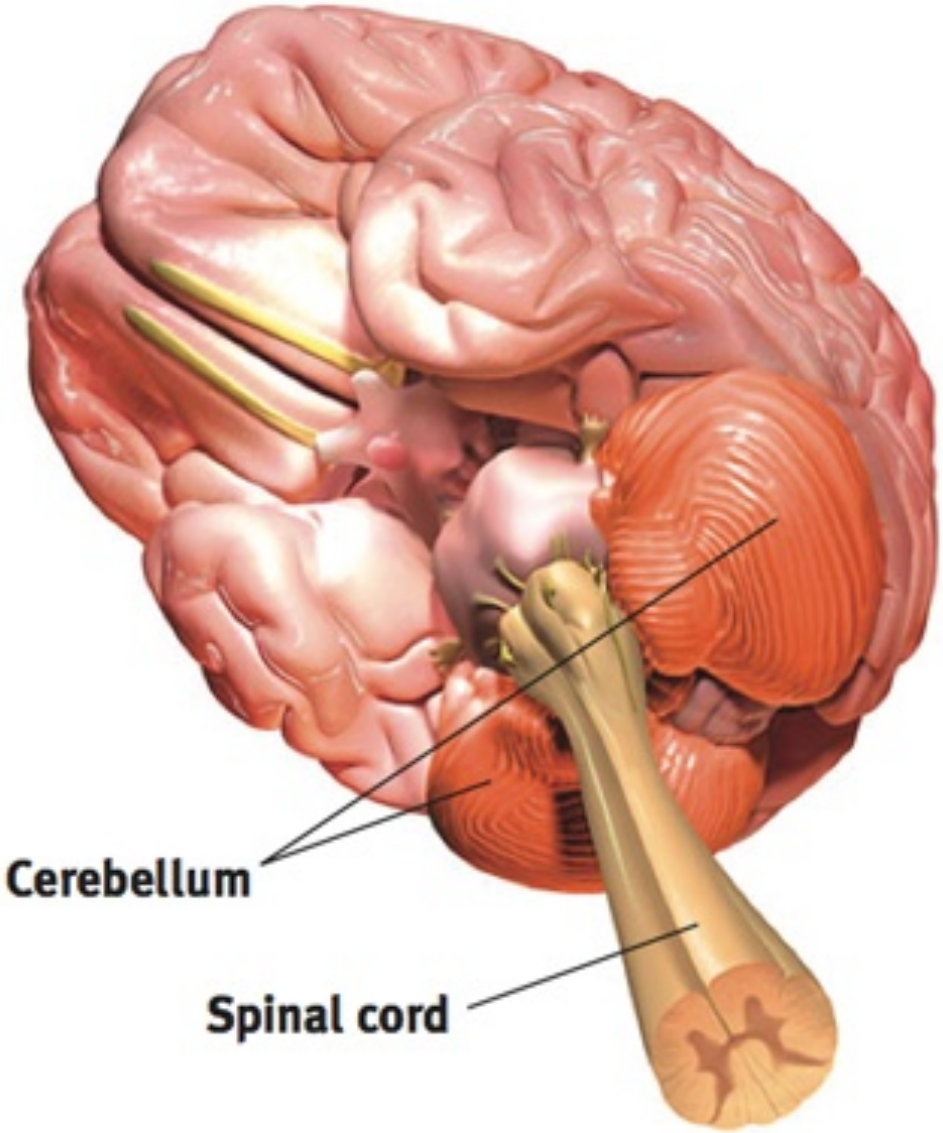

Cerebellum

The “little brain” attached to the rear of the brainstem. It helps coordinate voluntary movements and balance.

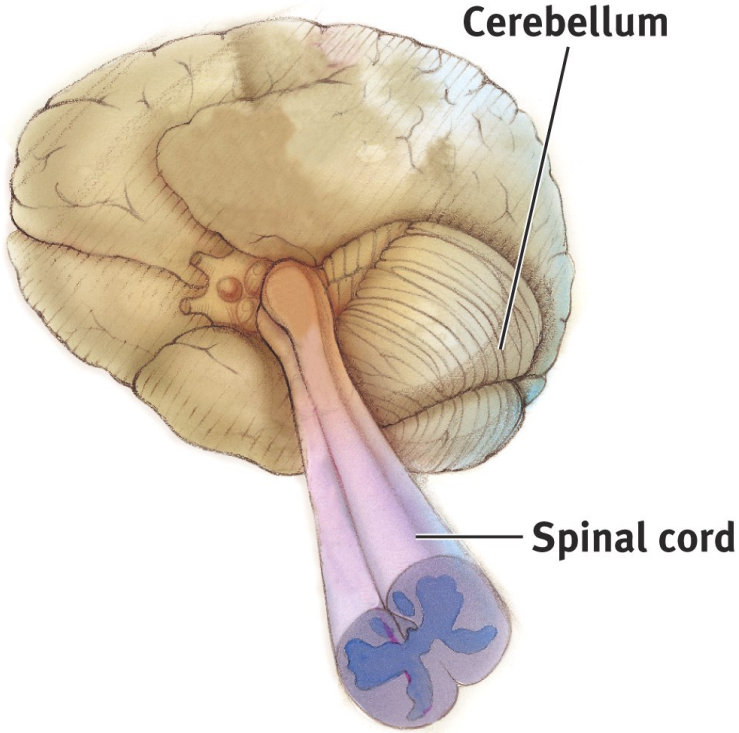

The Limbic System

The Limbic System is a doughnut-shaped system of neural structures at the border of the brainstem and cerebrum, associated with emotions such as fear, aggression and drives for food and sex. It includes the hippocampus, amygdala, and hypothalamus.

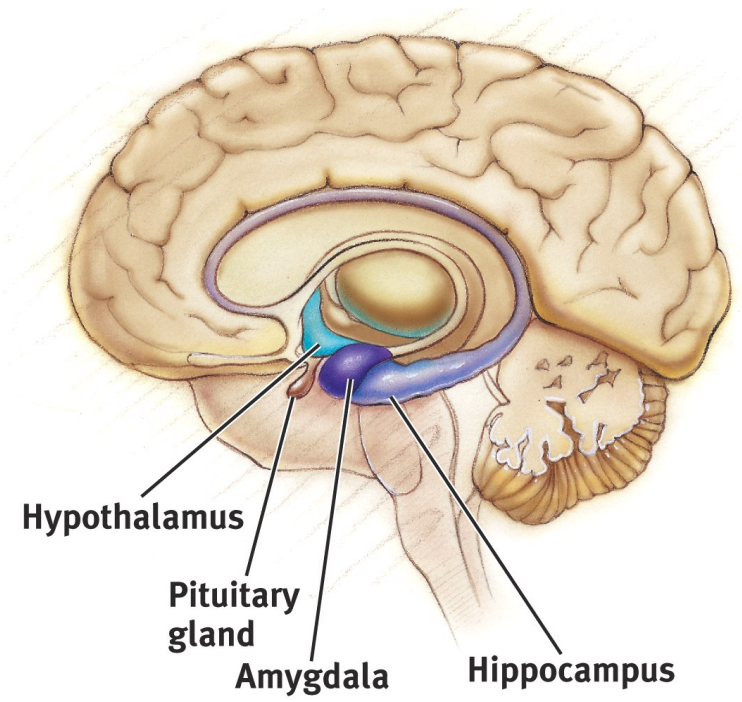

The Limbic System

- Limbic System
  - Hippocampus

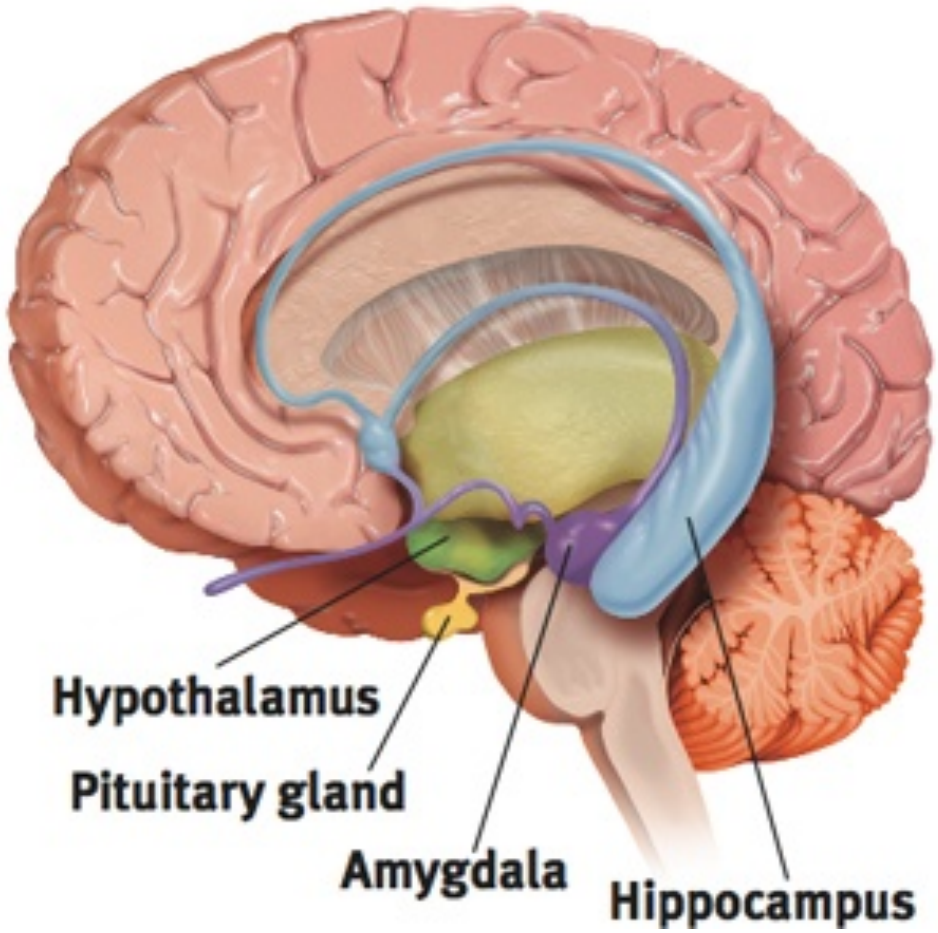

Hippocampus

- Hippocampus– structure that contributes to the formation of memories.
- Damage to the hippocampus has been implicated in the memory loss associated with Alzheimer's.

The Limbic System
The Amygdala

- Amygdala
  - Aggression and fear

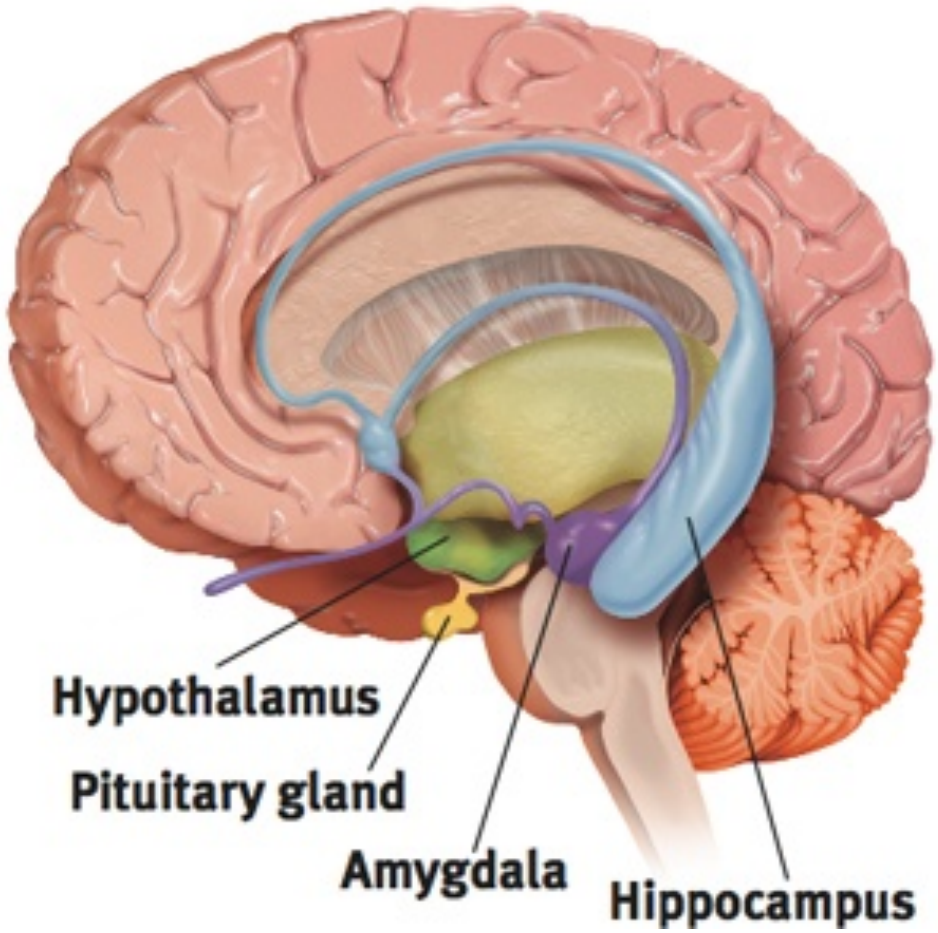

Amygdala

The Amygdala [ah-MIG-dah-la] consists of two almond-shaped neural clusters linked to the emotions of fear and anger.

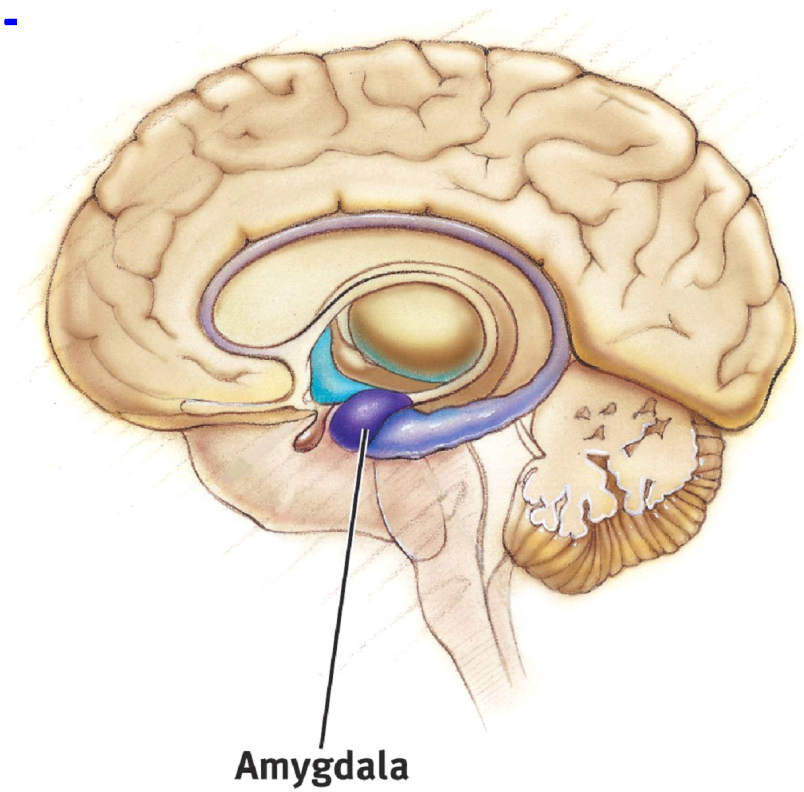

Amygdala and Emotion

- Identify emotion from facial expressions
- **Amygdala damage makes this task difficult**

Figure 2.19 The amygdala
Myers: Psychology, Eighth Edition

The Limbic System
The Hypothalamus

- Hypothalamus
  - Influence on the pituitary gland
  - Reward Centers
  - Reward deficiency syndrome

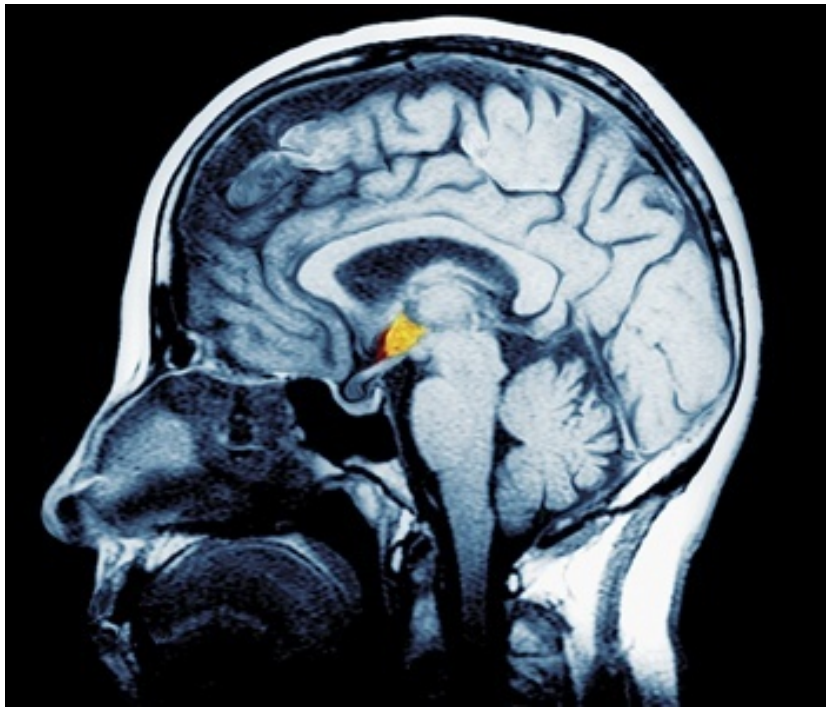

Hypothalamus

The Hypothalamus lies below (**hypo**) the thalamus. It directs several maintenance activities like eating, drinking, body temperature, and control of emotions.

It helps govern the endocrine system via the pituitary glanc

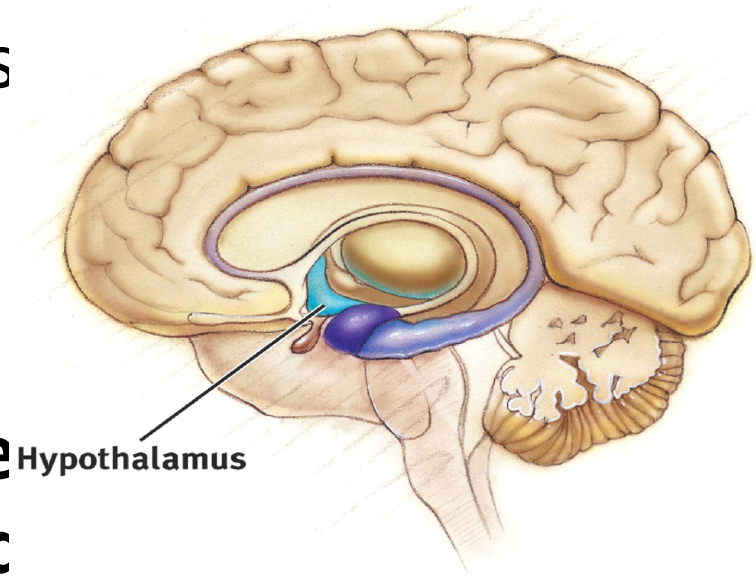

Reward Center

Rats cross an electrified grid for self-stimulation when electrodes are placed in the reward (hypothalamus) center.

When the limbic system is manipulated, a rat will navigate fields or climb up a tree.

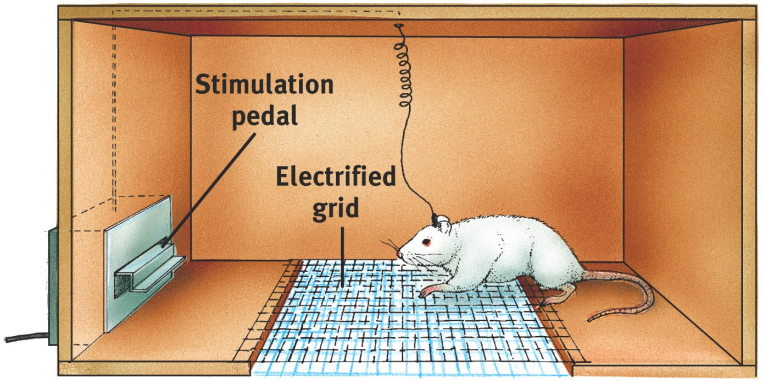

Sanjiv Talwar, SUNY Downstate

The Cerebral Cortex

Introduction

- Cerebrum
  - Cerebral cortex

Structure of the Cortex

- Glial cells ("glue cells")
- Lobes
  - Frontal lobes
  - Parietal lobes
  - Occipital lobes
  - Temporal lobes

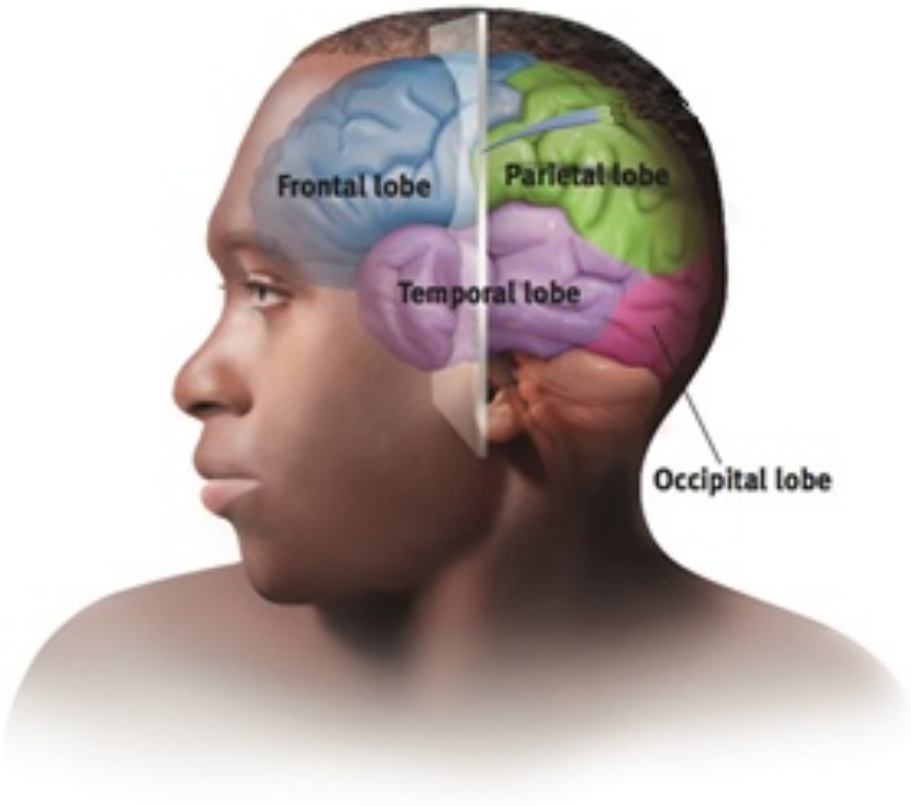

The Cerebral Cortex

- Cerebral Cortex
  - the intricate fabric of interconnected neural cells that covers the cerebral hemispheres
  - the body's ultimate control and information processing center
- Glial Cells
  - cells in the nervous system that support, nourish, and protect neurons

Kinds of Glial Cells

Astrocytes provide nutrition to neurons. Oligodendrocytes and Schwann cells insulate neurons as myelin.

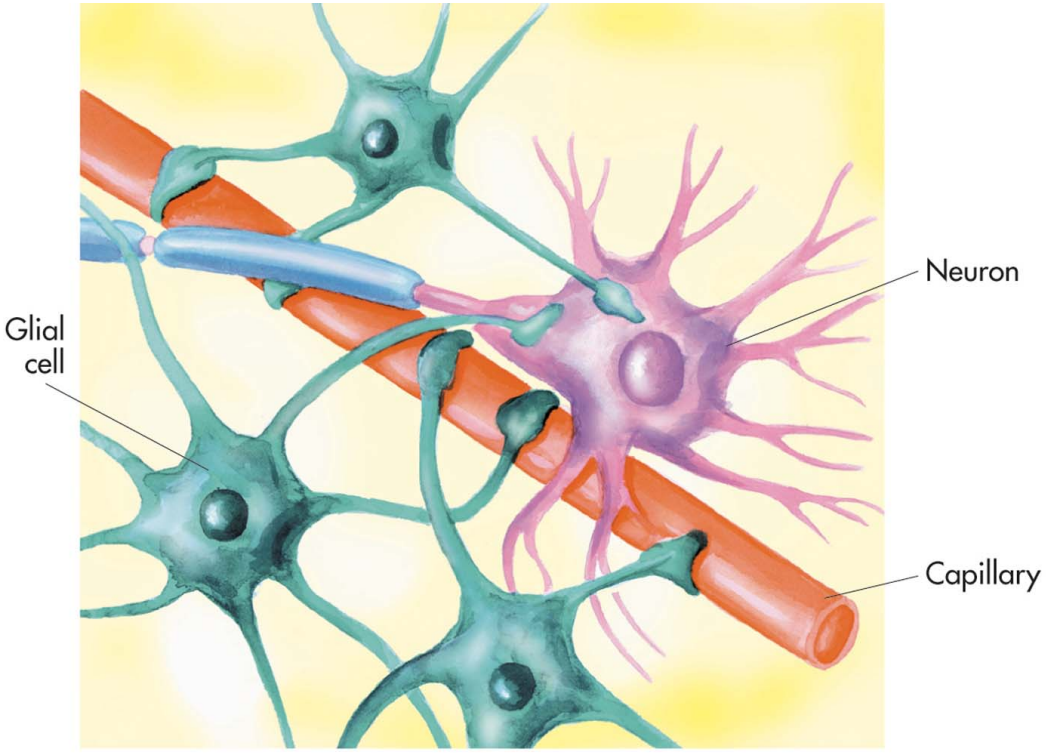

Astrocytes

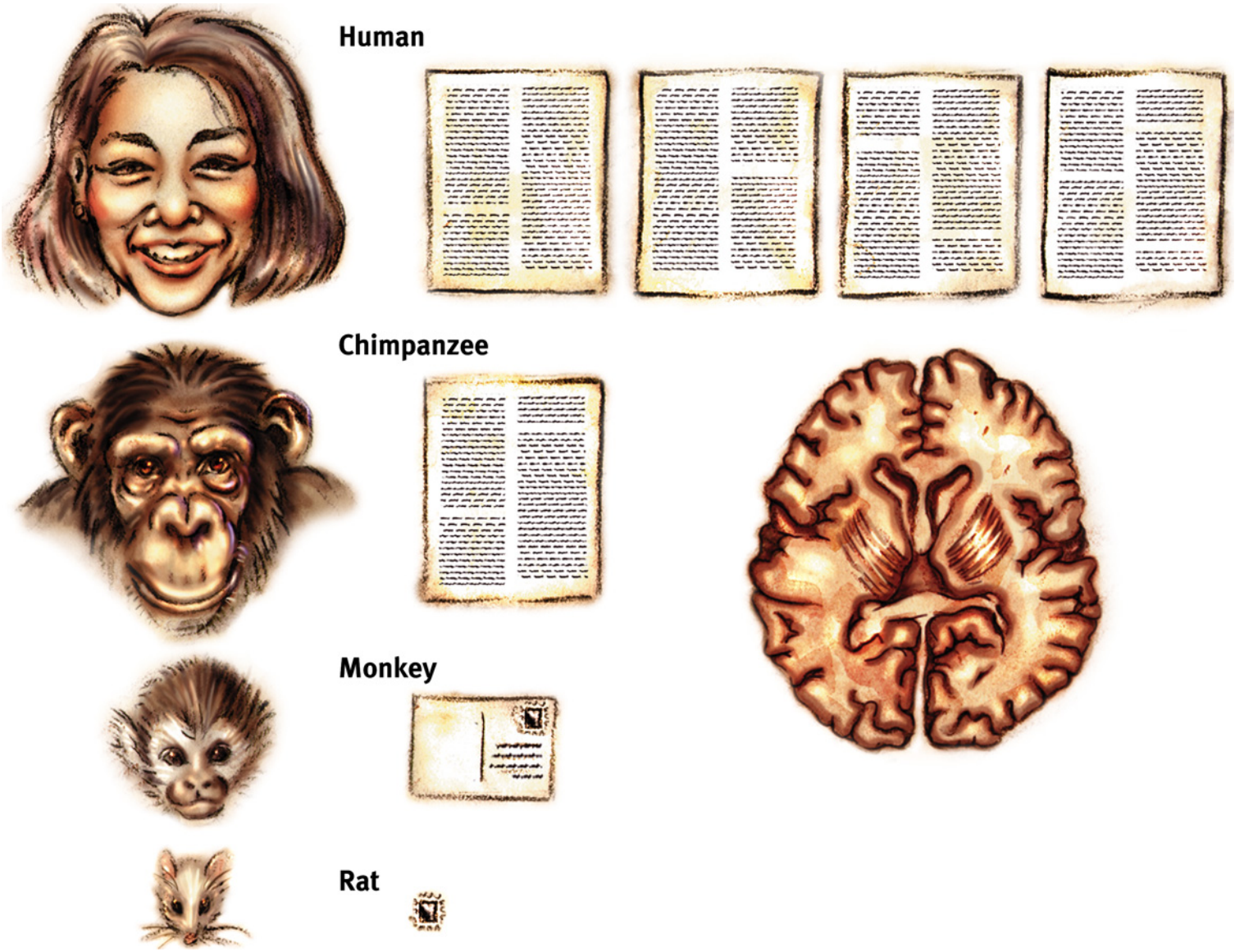

Figure 2.24 The cerebral cortex
Myers: Psychology, Eighth Edition

The Cerebral Cortex

- Frontal Lobes
  - involved in speaking and muscle movements and in making plans and judgments
- Parietal Lobes
  - include the sensory cortex & processes somatic information
- Occipital Lobes
  - include the visual areas, which receive visual information from the opposite visual field
- Temporal Lobes
  - include the auditory areas

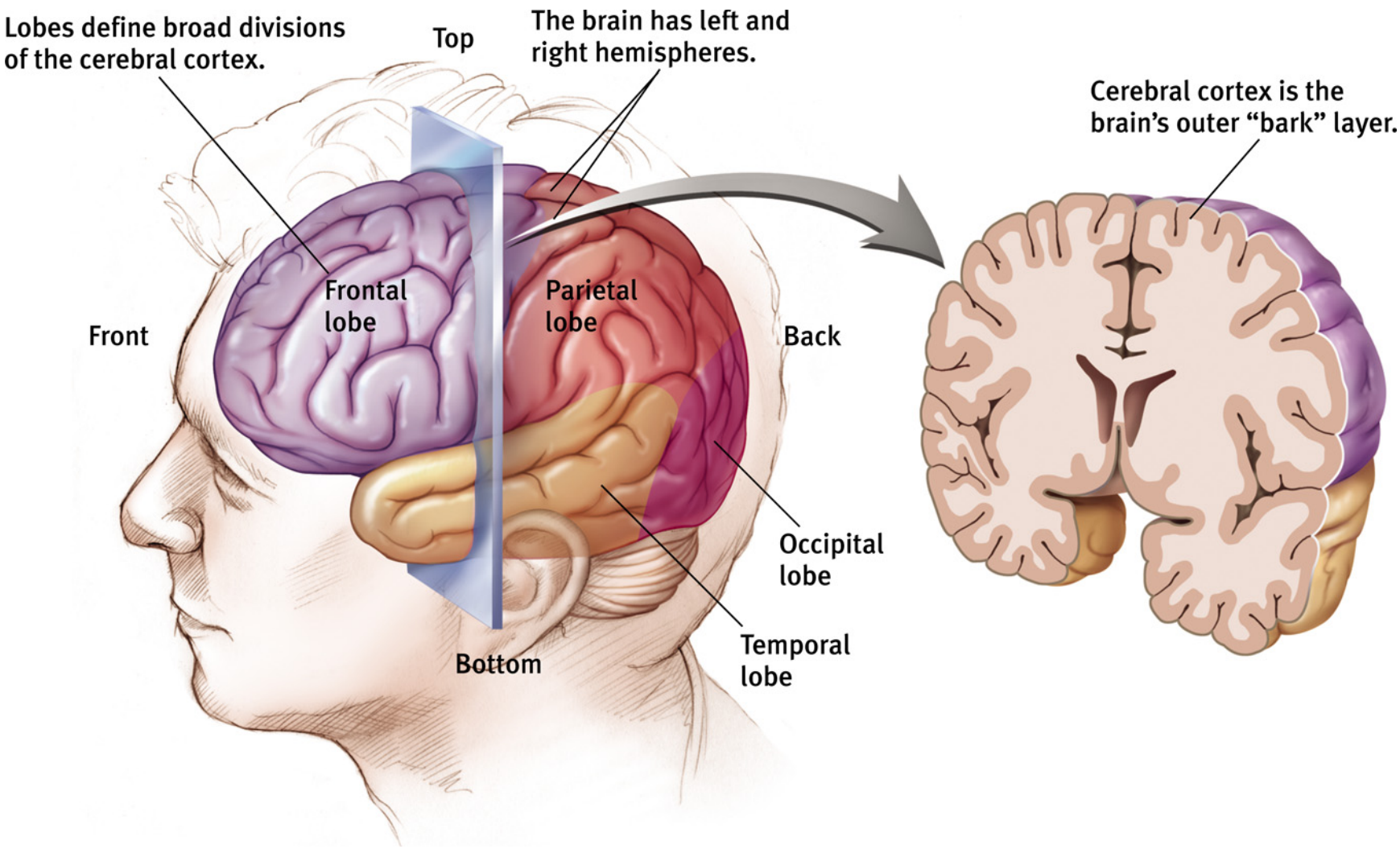

Figure 2.25 The cortex and its basic subdivisions
Myers: Psychology, Eighth Edition

The Cerebral Cortex

- Motor Cortex
  - area at the rear of the frontal lobes that controls voluntary movements
- Sensory Cortex
  - area at the front of the parietal lobes that registers and processes body sensations

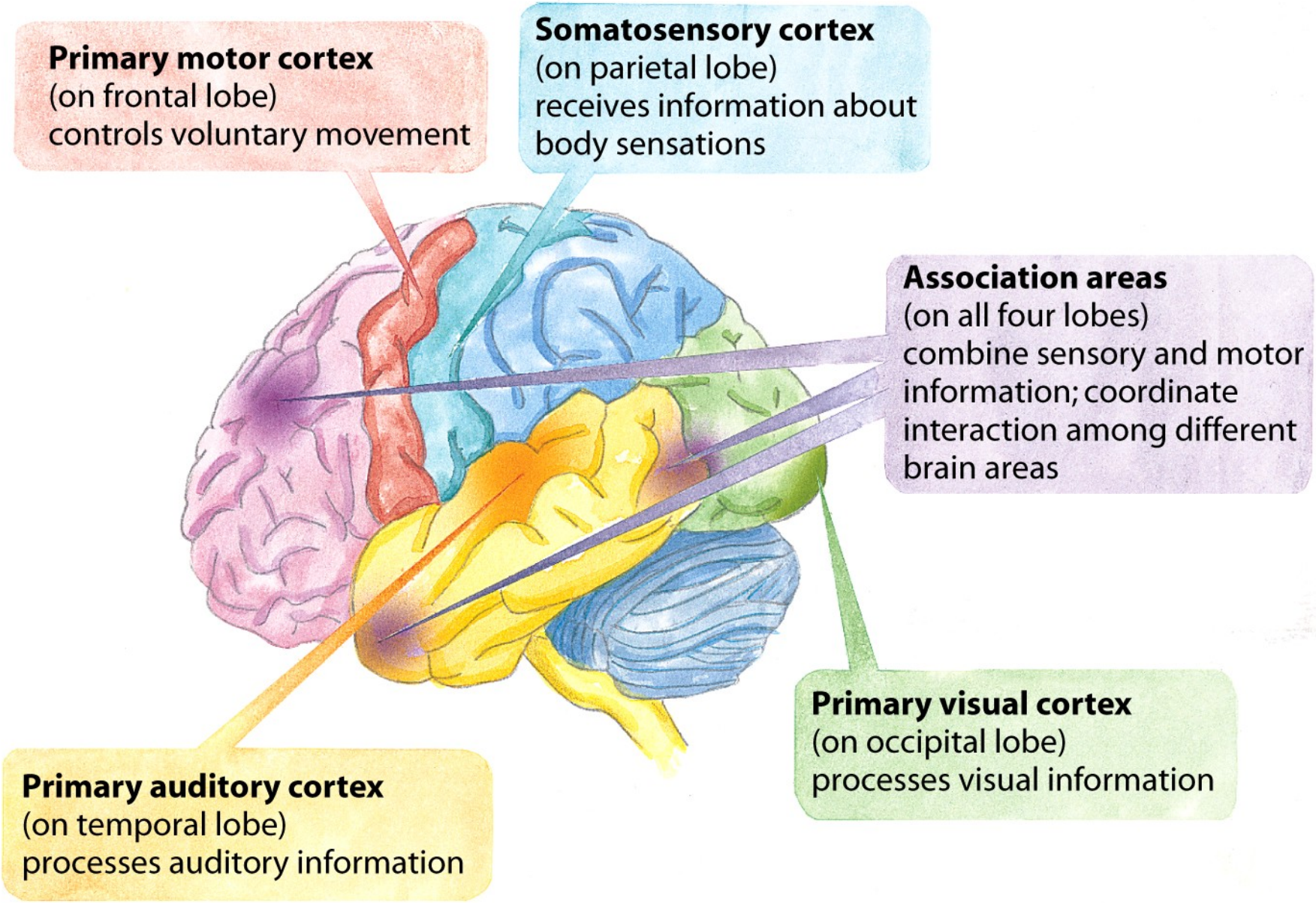
Primary motor cortex
(on frontal lobe)
controls voluntary movement
Somatosensory cortex
(on parietal lobe)
receives information about
body sensations
Association areas
(on all four lobes)
combine sensory and motor
information; coordinate
interaction among different
brain areas
Primary visual cortex
(on occipital lobe)
processes visual information
Primary auditory cortex
(on temporal lobe)
processes auditory information

Functions of the Cerebral Cortex

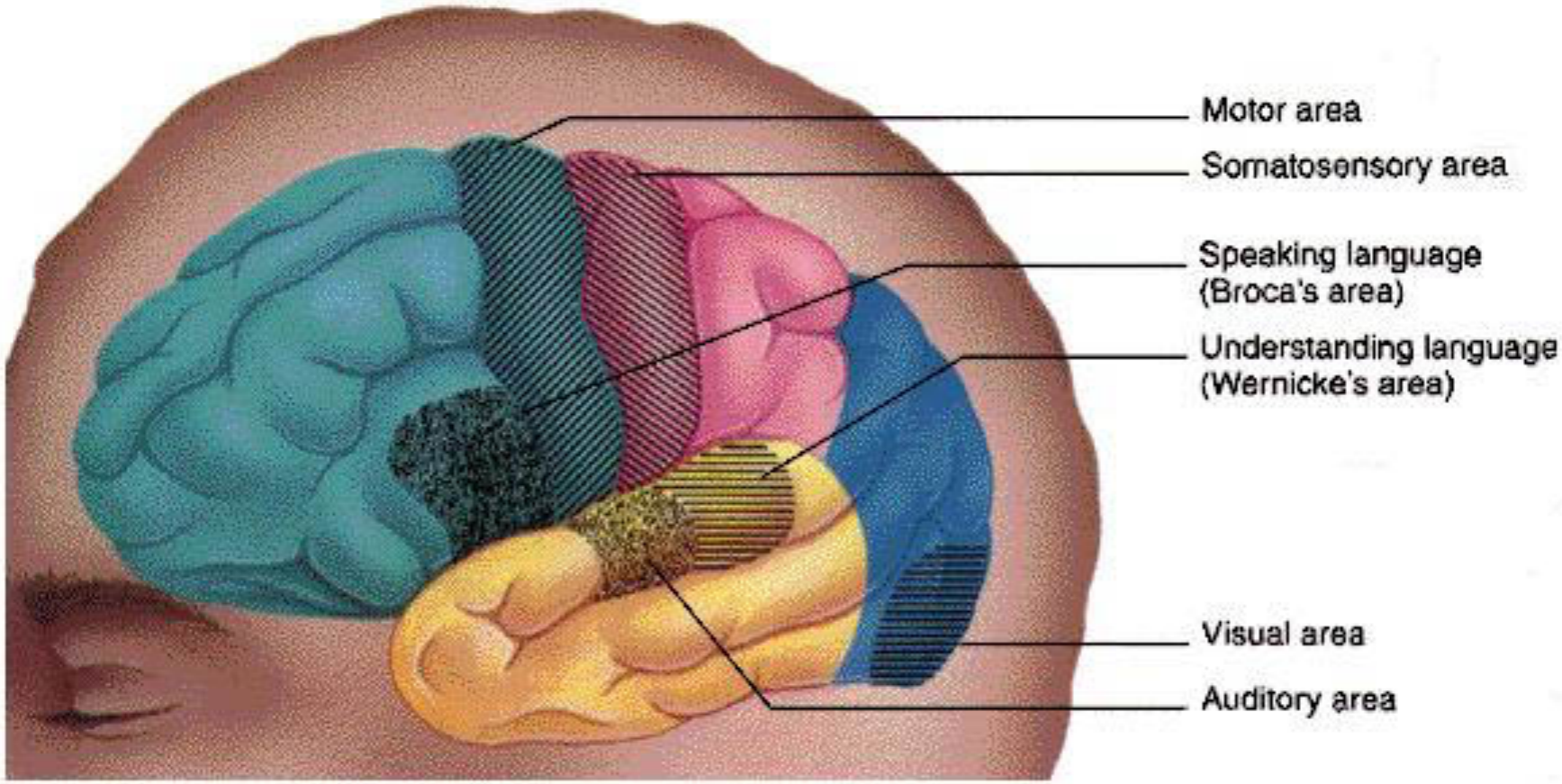

Functions of the Cortex
Motor Functions

- Motor Cortex
- Mapping the Motor Cortex
- Neural Prosthetics

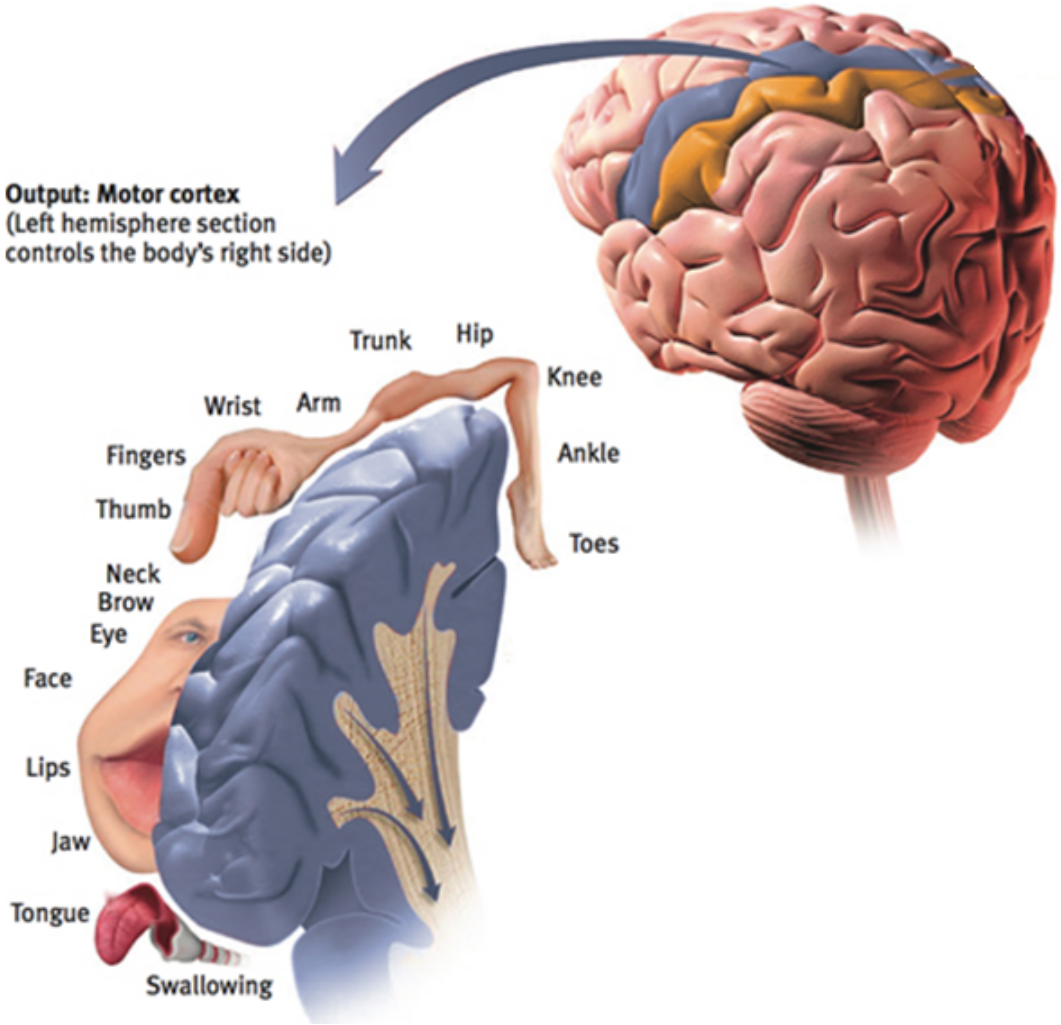

Functions of the Cortex
Sensory Functions

- Sensory cortex

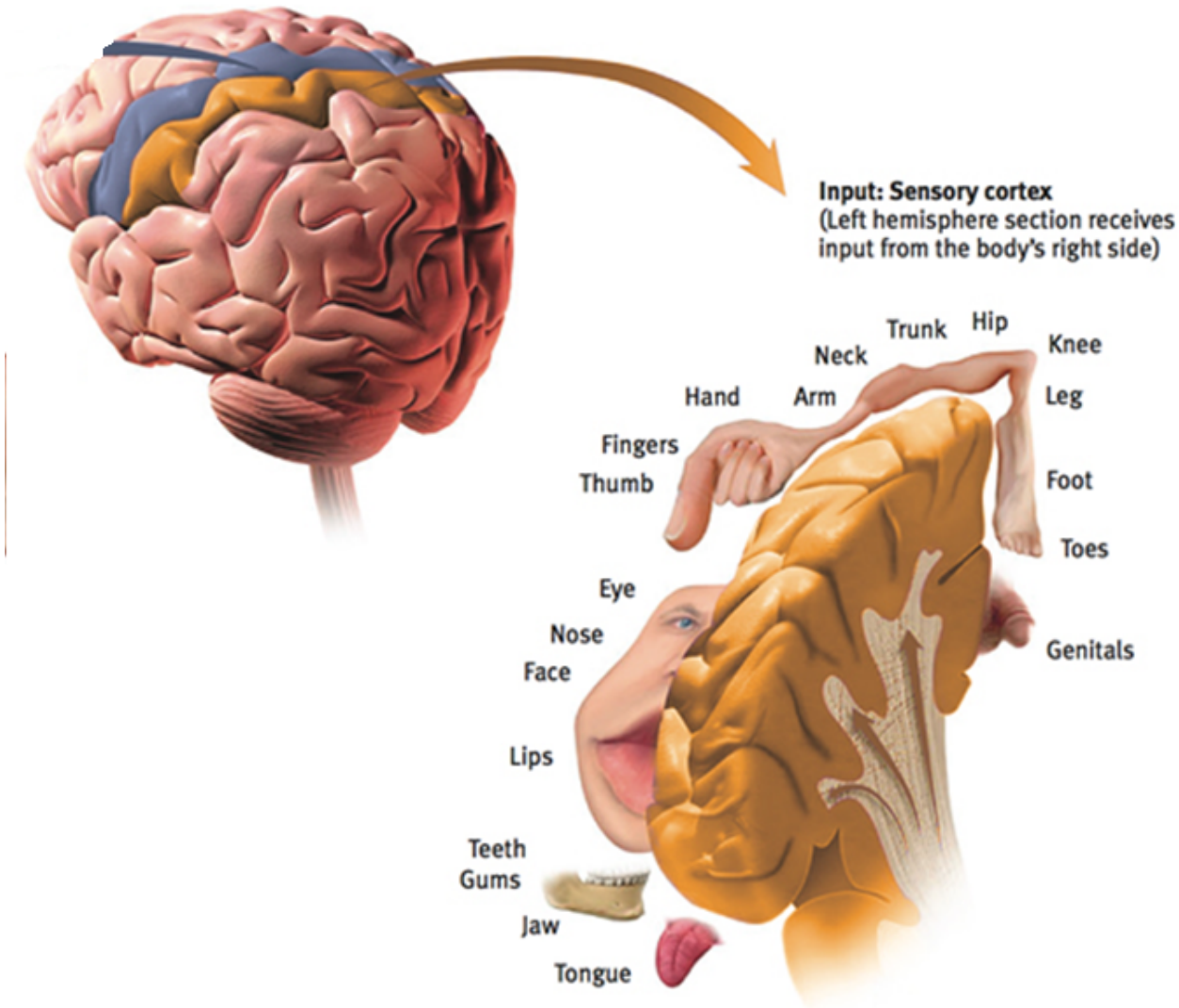

Functions of the Cortex

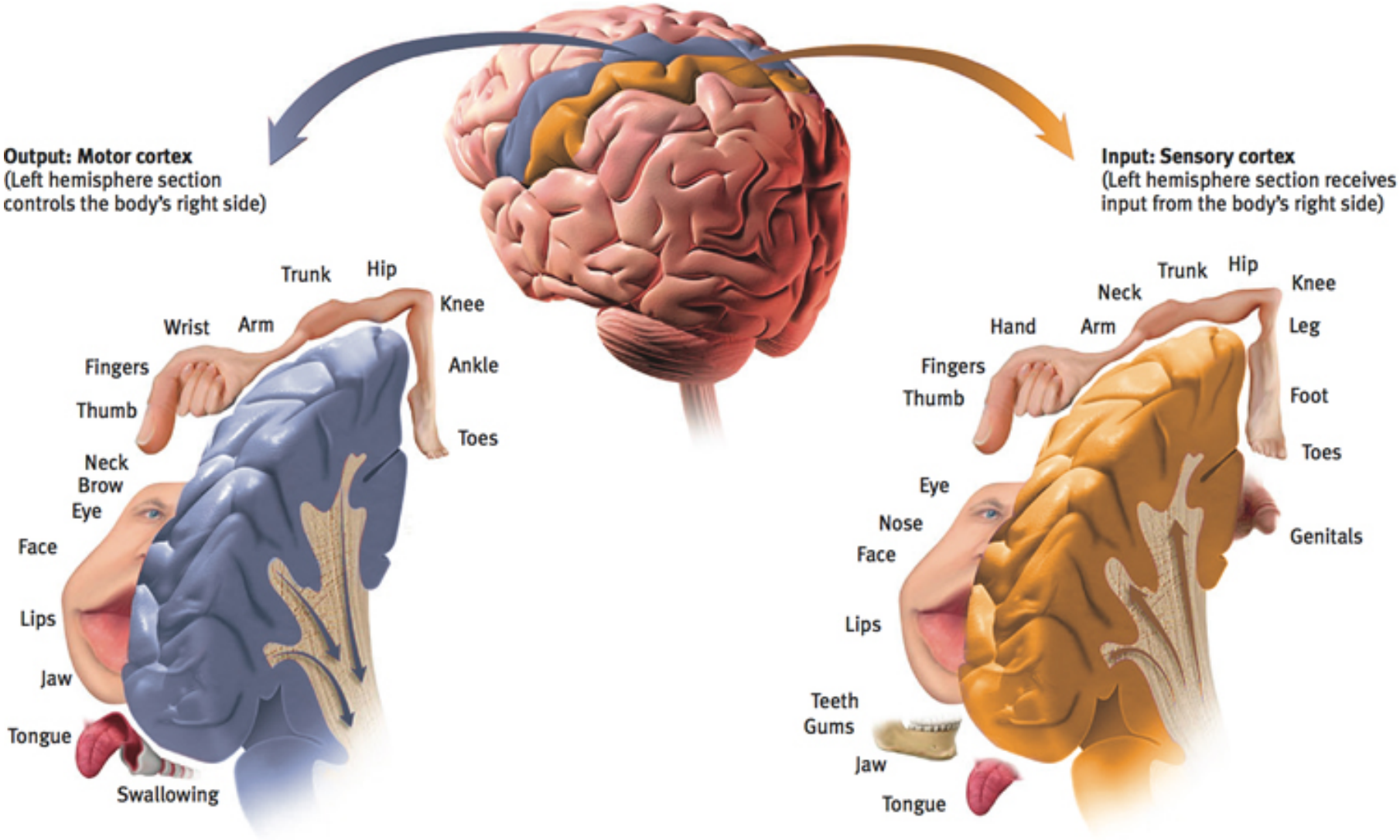

Visual Function

The functional MRI scan shows the visual cortex is active as the subject looks at faces.

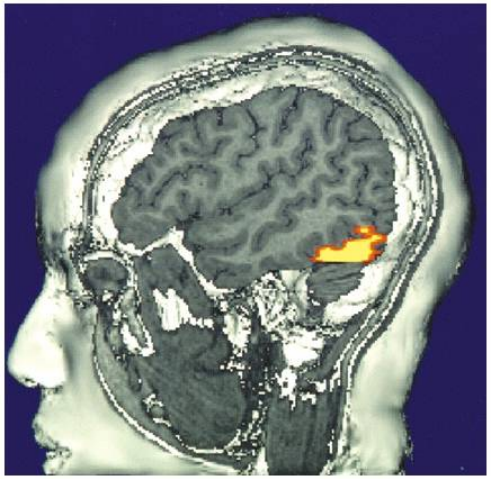

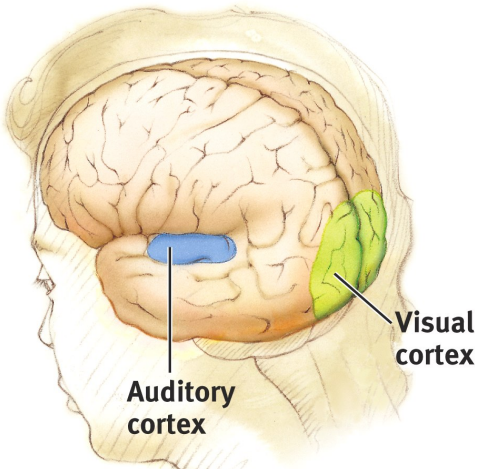

Auditory Function

The functional MRI scan shows the auditory cortex is active in patients who hallucinate.

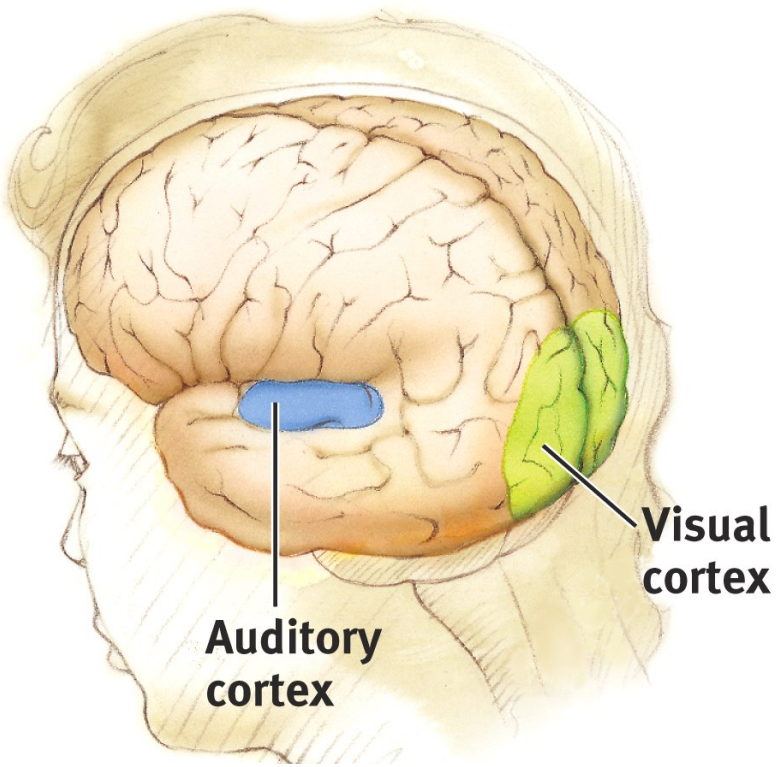

Functions of the Cortex
Association Areas

- Association areas
  - Frontal lobes
    - Phineas Gage
  - Parietal lobes
  - Temporal lobes

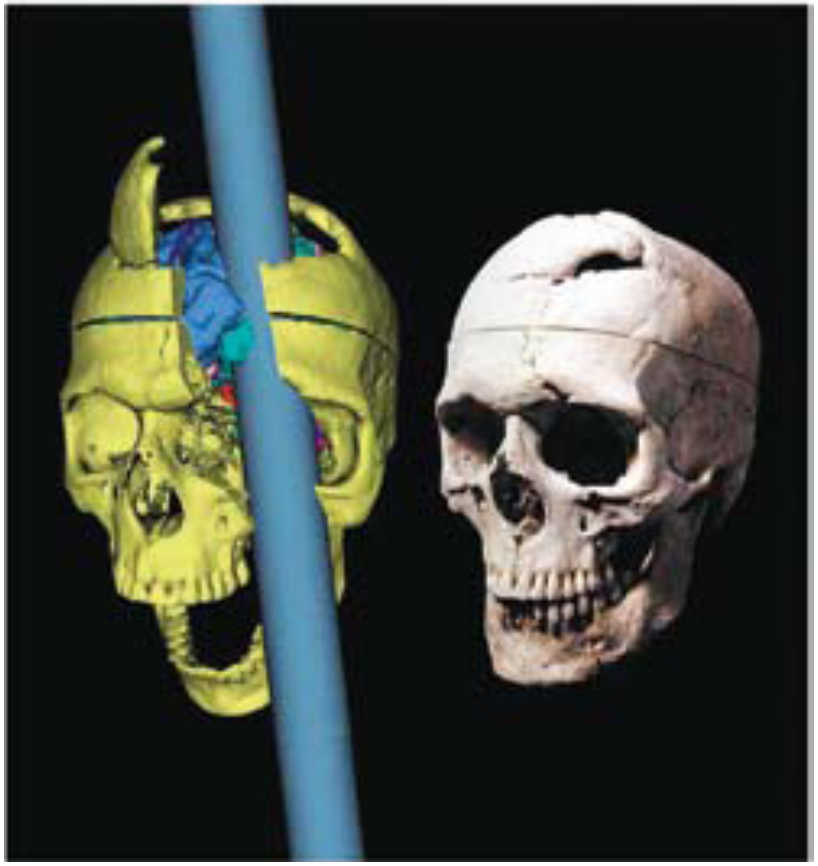

Association Areas

- More intelligent animals have increased “uncommitted” or association areas of the cortex

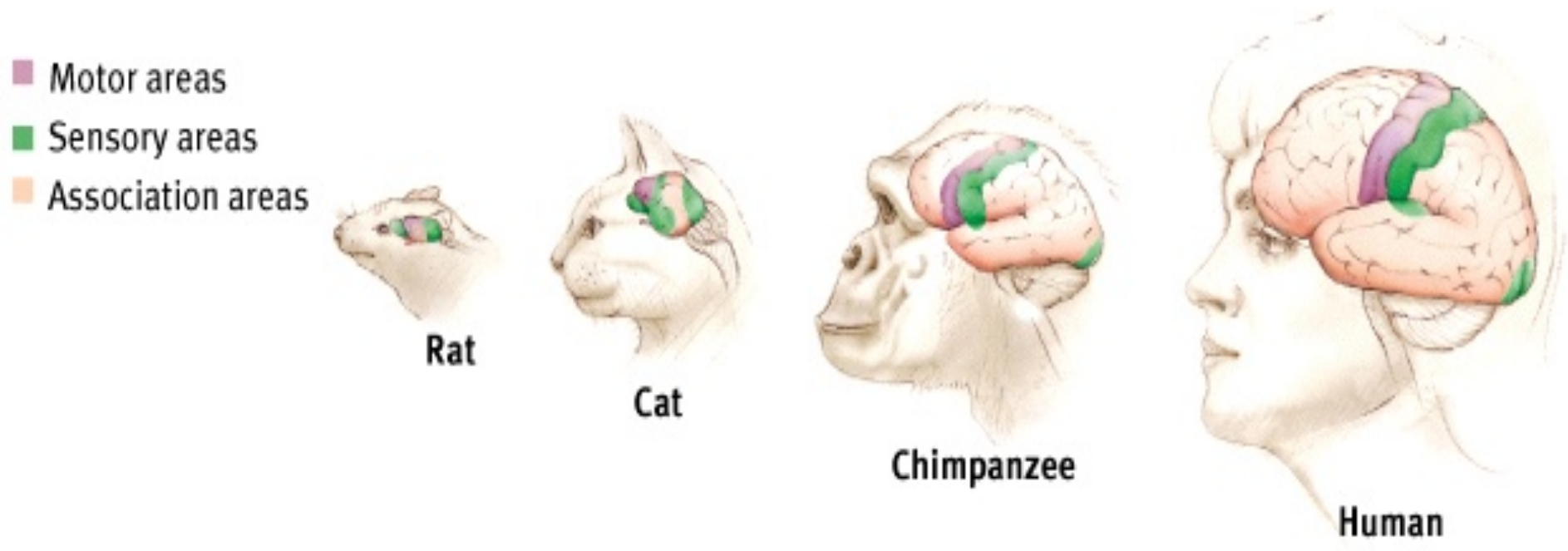

Language

- Aphasia
  - Broca's area
  - Wernicke's area

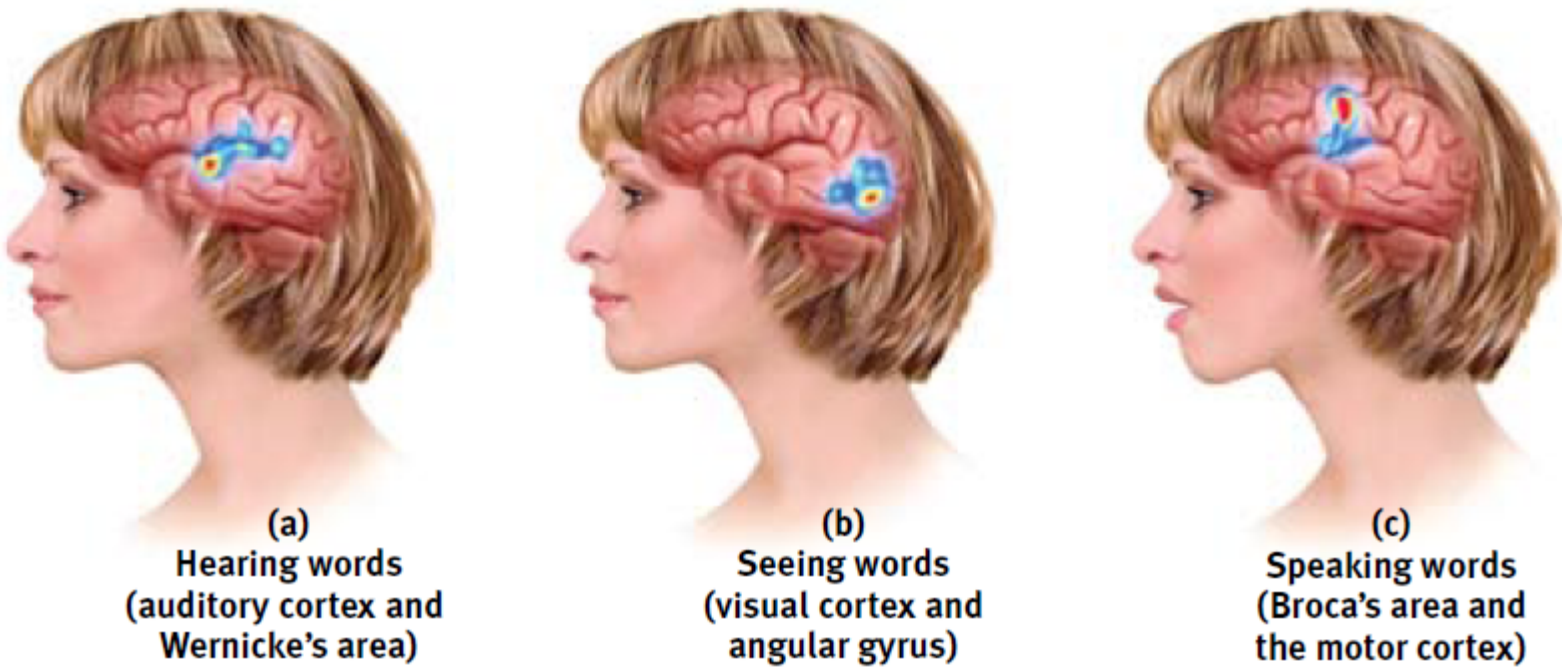

Language

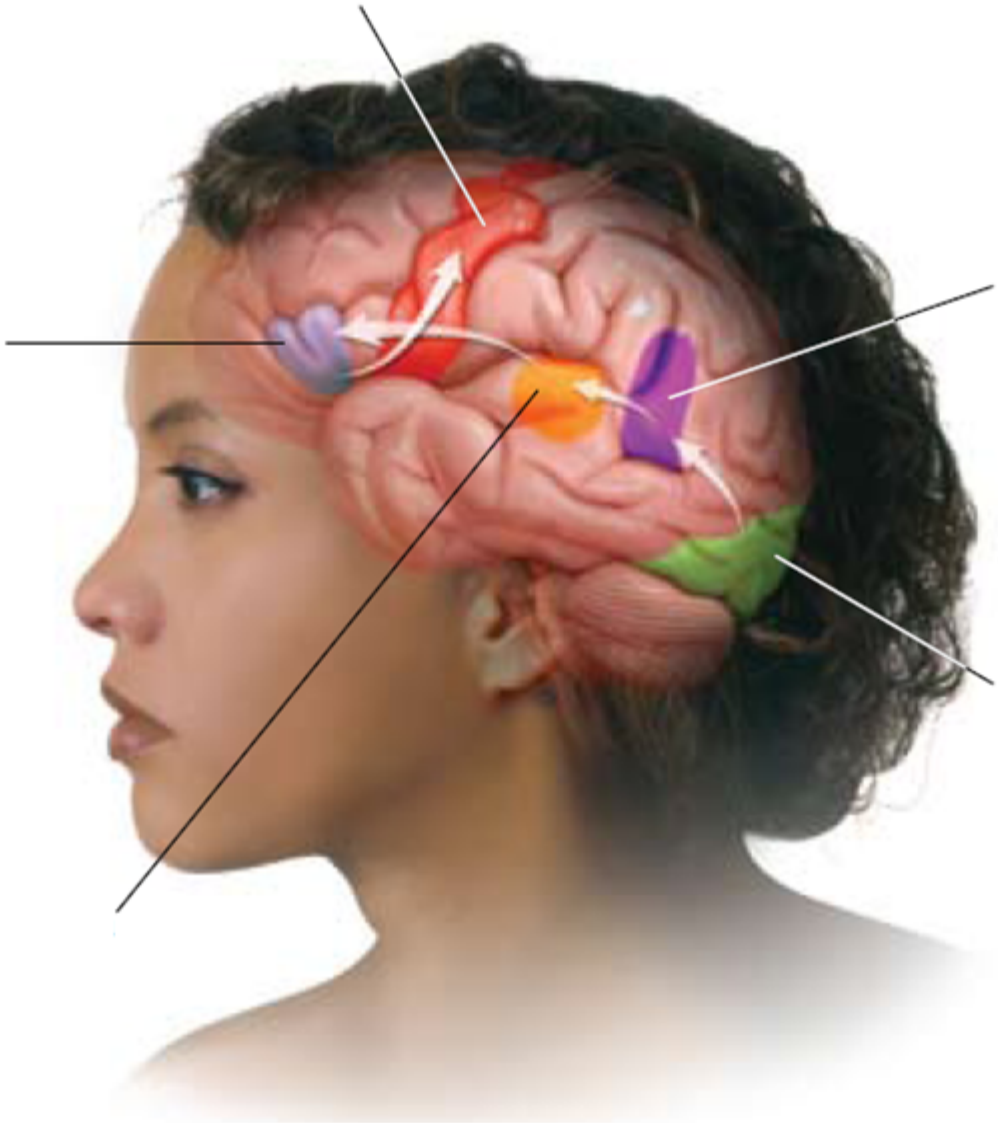

Language

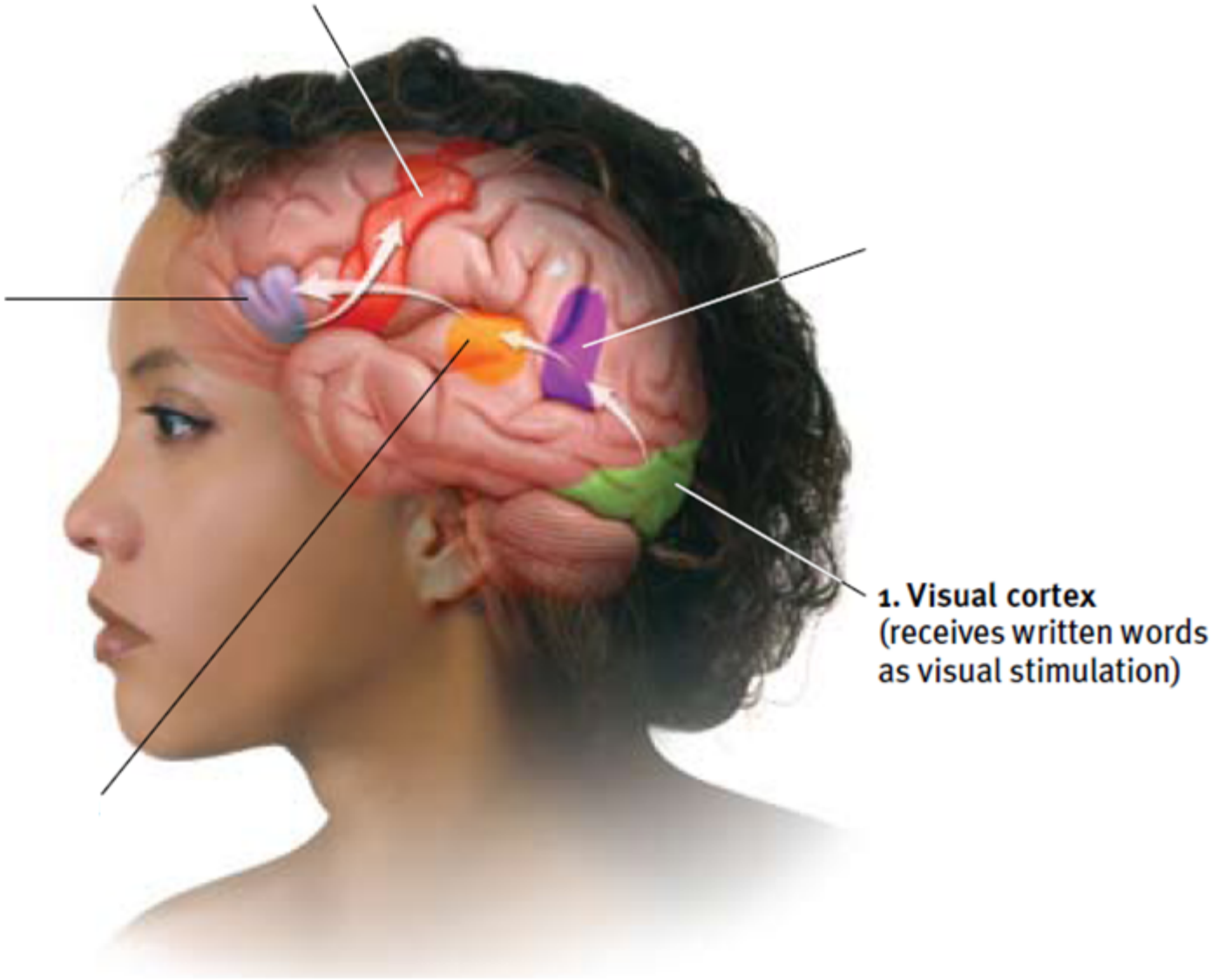
1. Visual cortex
(receives written words
as visual stimulation)

Language

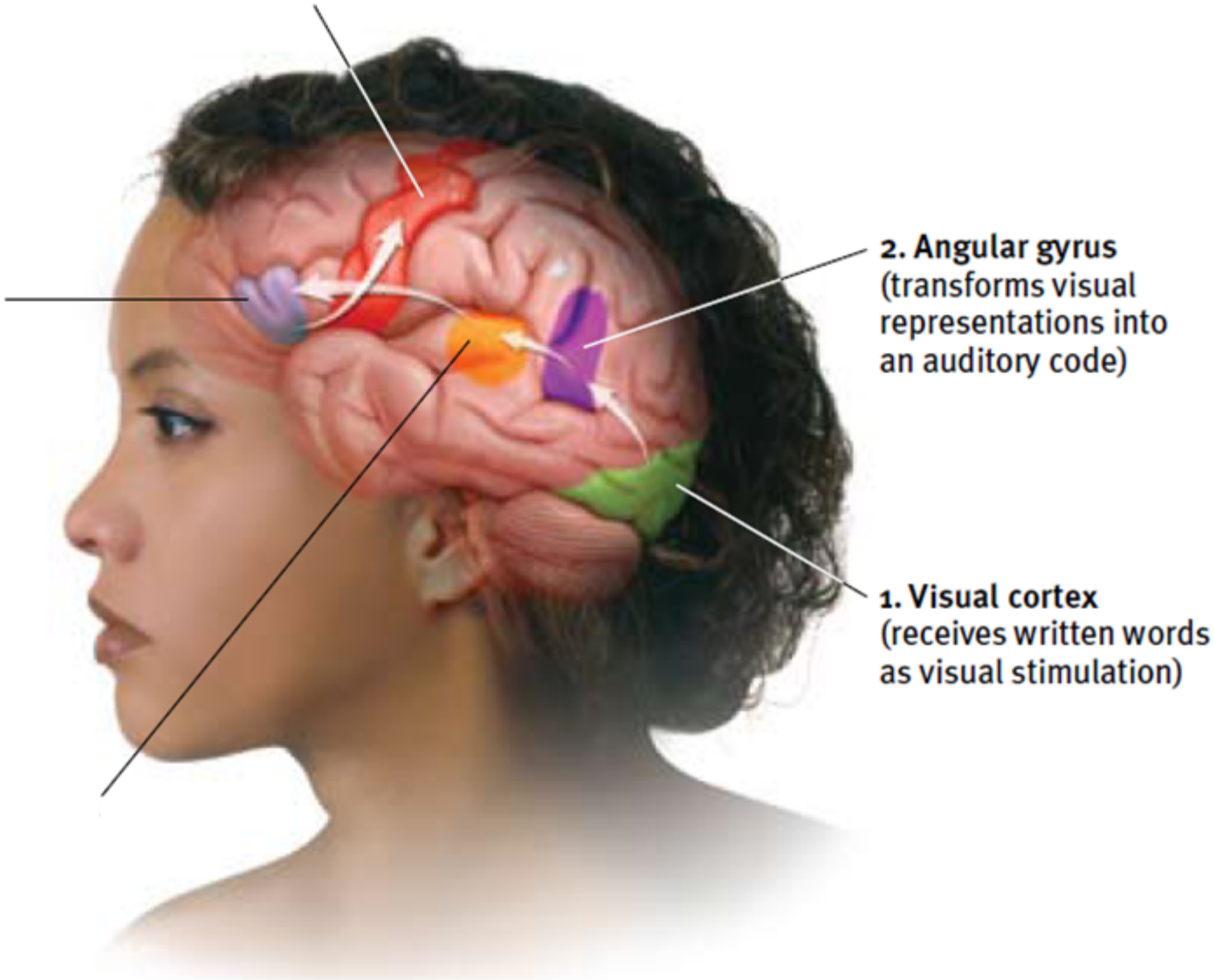
2. Angular gyrus
(transforms visual representations into an auditory code)
1. Visual cortex
(receives written words as visual stimulation)

Language

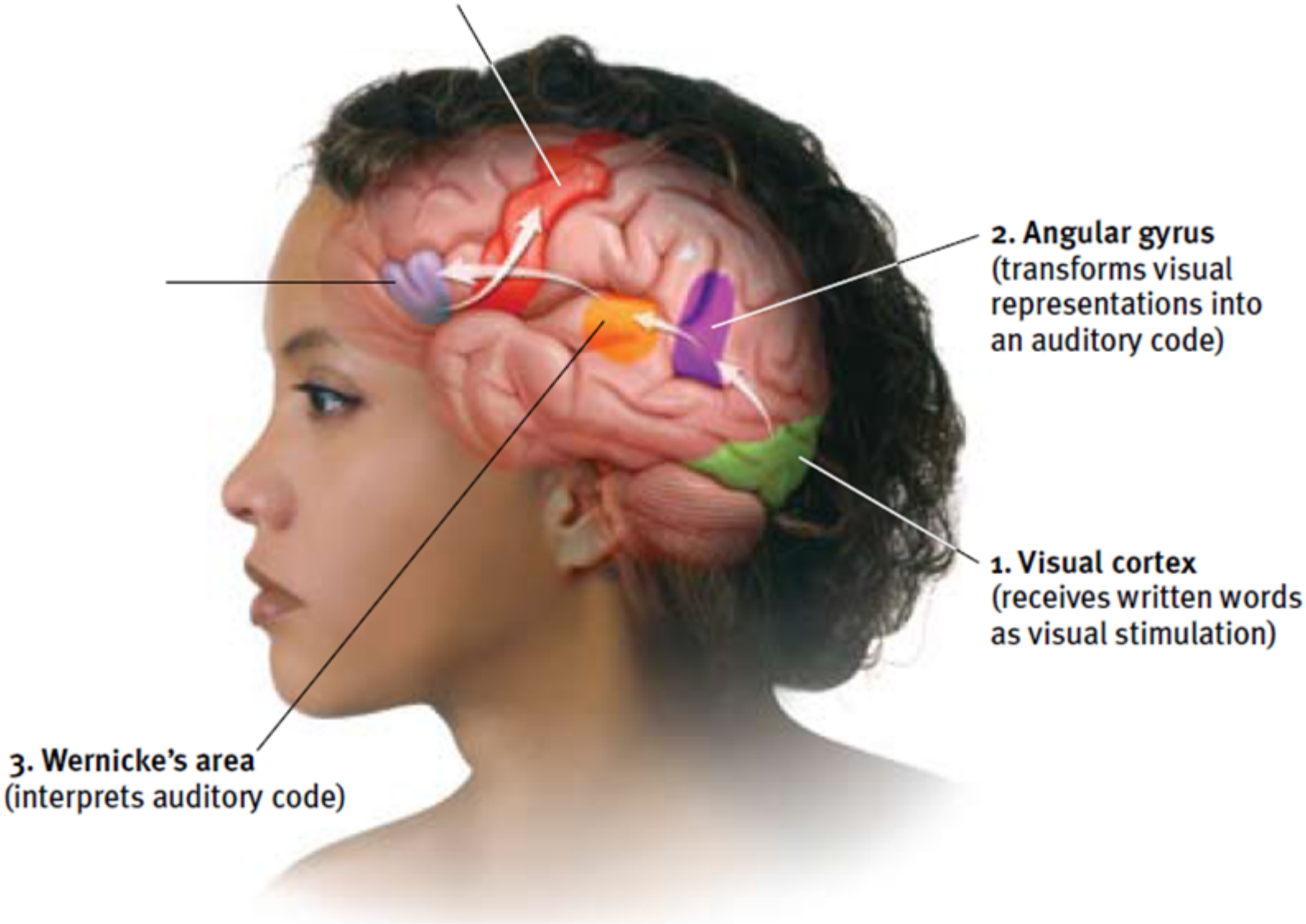
2. Angular gyrus
(transforms visual representations into an auditory code)
1. Visual cortex
(receives written words as visual stimulation)
3. Wernicke's area
(interprets auditory code)

Language

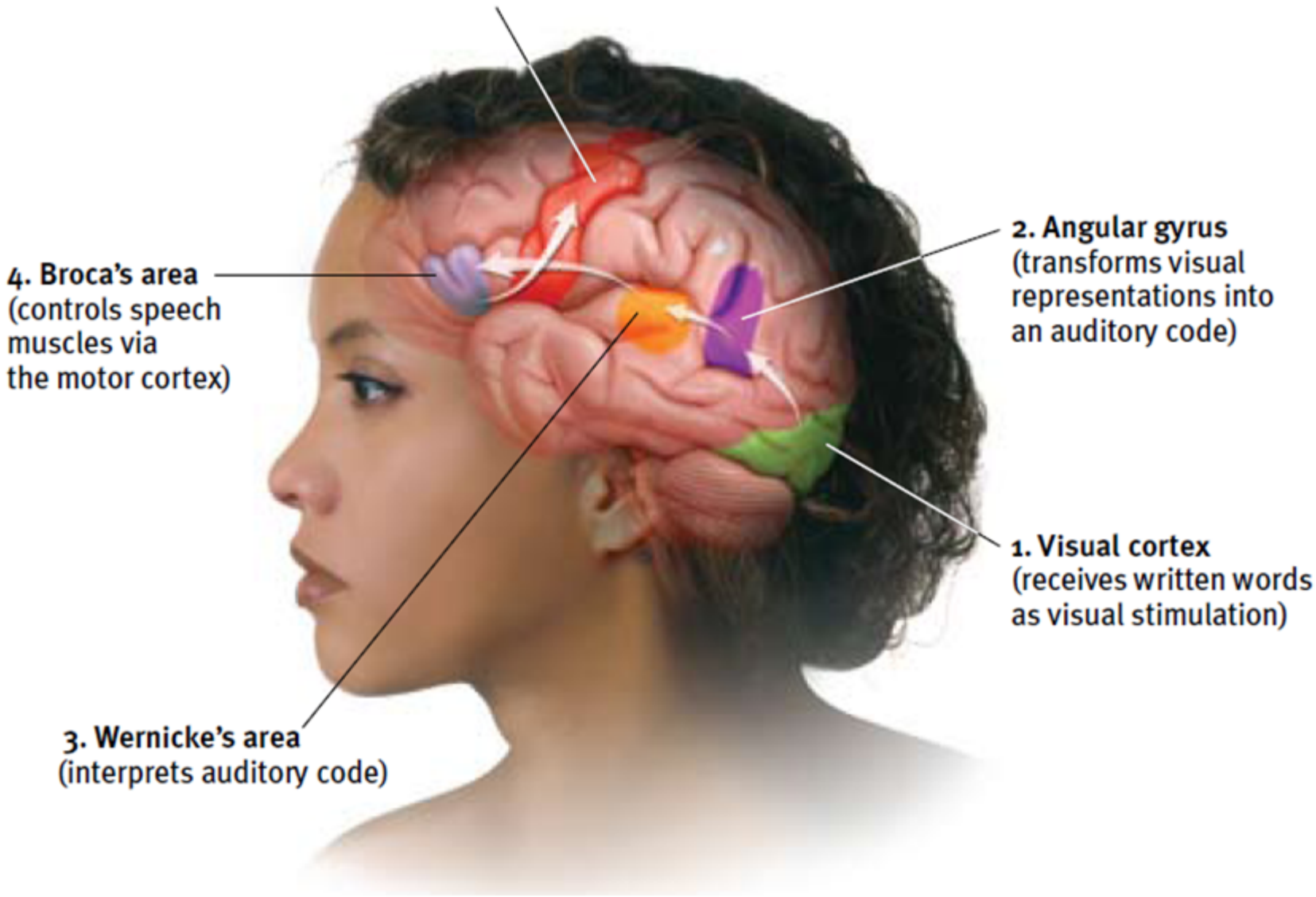
4. Broca's area
(controls speech
muscles via
the motor cortex)
2. Angular gyrus
(transforms visual
representations into
an auditory code)
1. Visual cortex
(receives written words
as visual stimulation)
3. Wernicke's area
(interprets auditory code)

Language

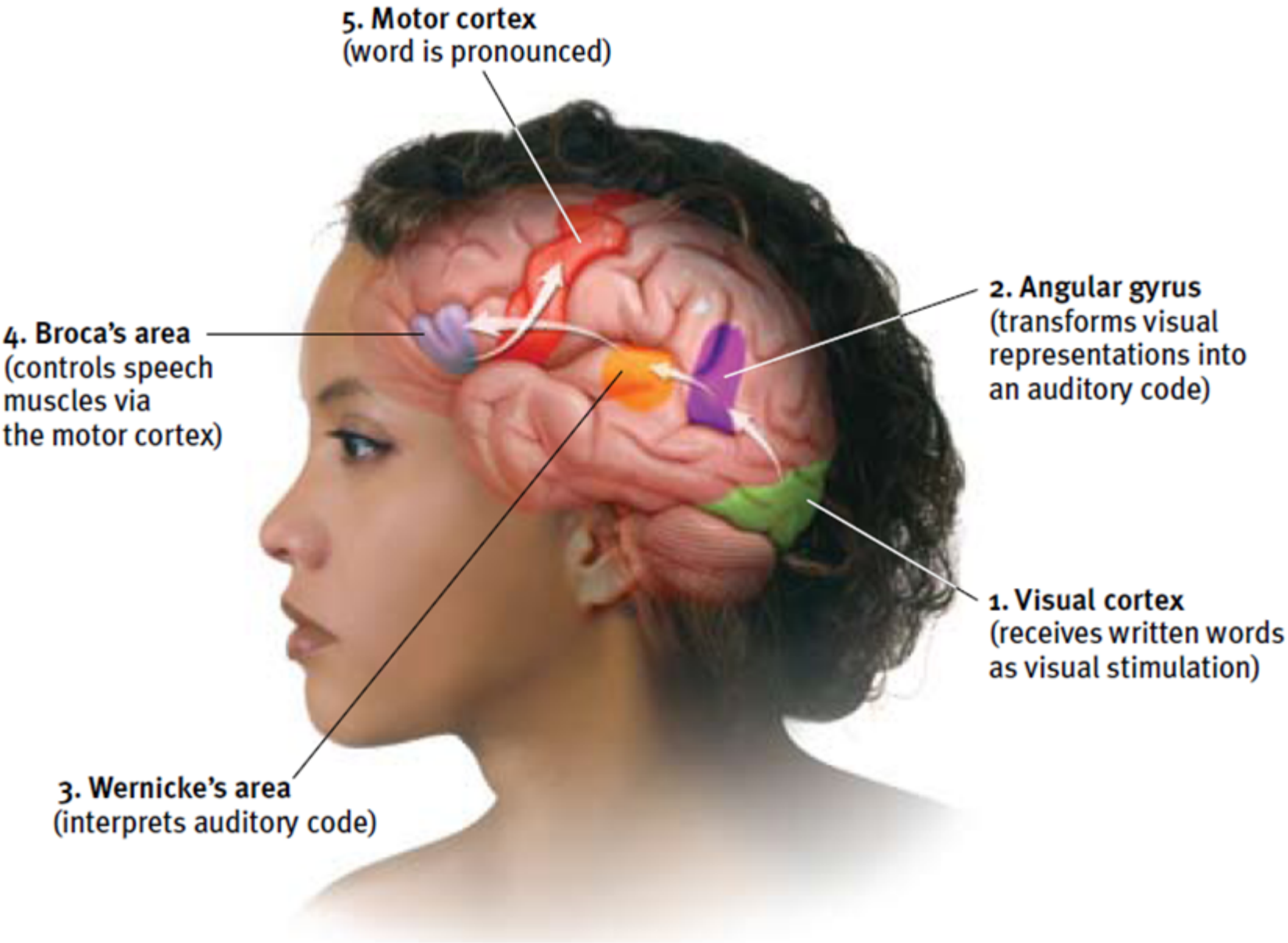
5. Motor cortex
(word is pronounced)
4. Broca's area
(controls speech
muscles via
the motor cortex)
2. Angular gyrus
(transforms visual
representations into
an auditory code)
1. Visual cortex
(receives written words
as visual stimulation)
3. Wernicke's area
(interprets auditory code)

The Brain's Plasticity

- Brain Damage
  - Plasticity
  - Constraint-induced therapy
  - Neurogenesis

Our Divided Brain

Splitting the Brain

- Vogel and Bogen
  - Corpus-callosum
  - Split brain
  - Myers and Gazzaniga

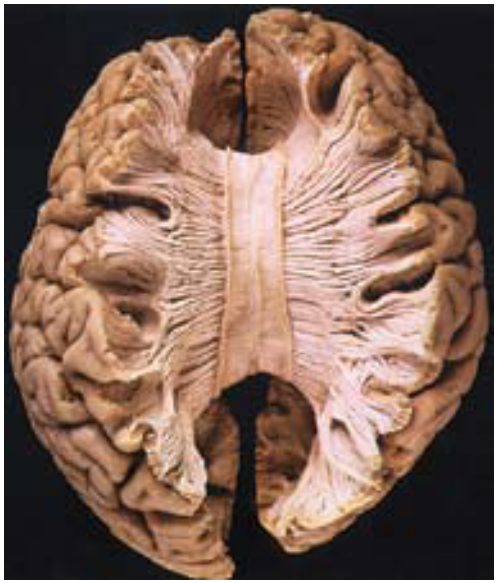



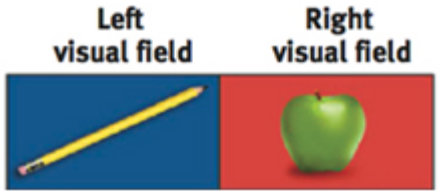
Left
visual field
Right
visual field


Left
visual field
Right
visual field
Optic
nerves

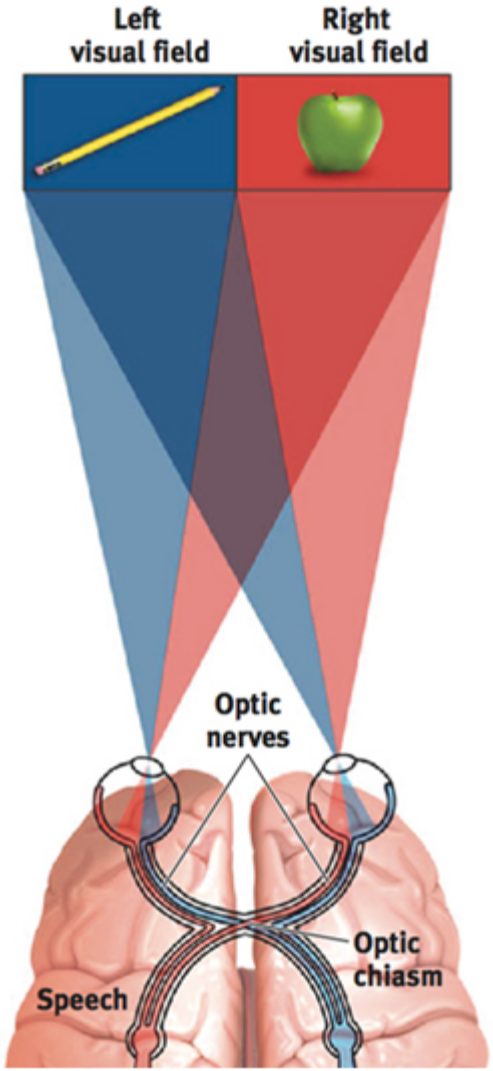
Left
visual field
Right
visual field
Optic
nerves
Optic
chiasm
Speech

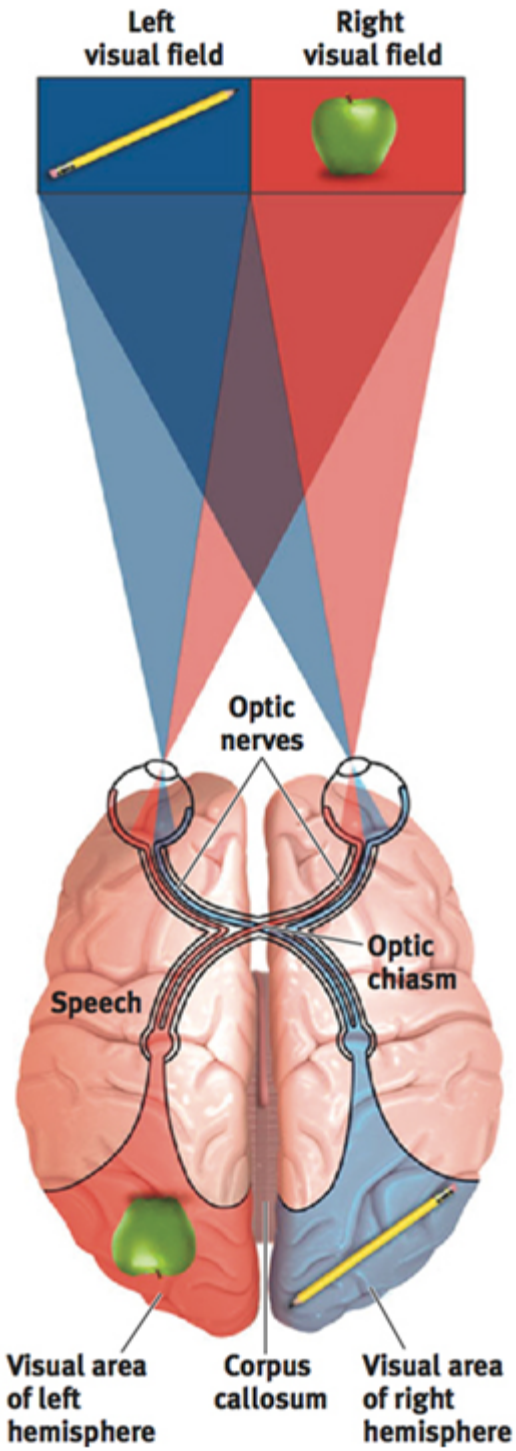
Left
visual field
Right
visual field
Optic
nerves
Optic
chiasm
Speech
Visual area
of left
hemisphere
Corpus
callosum
Visual area
of right
hemisphere

(a)

(b)

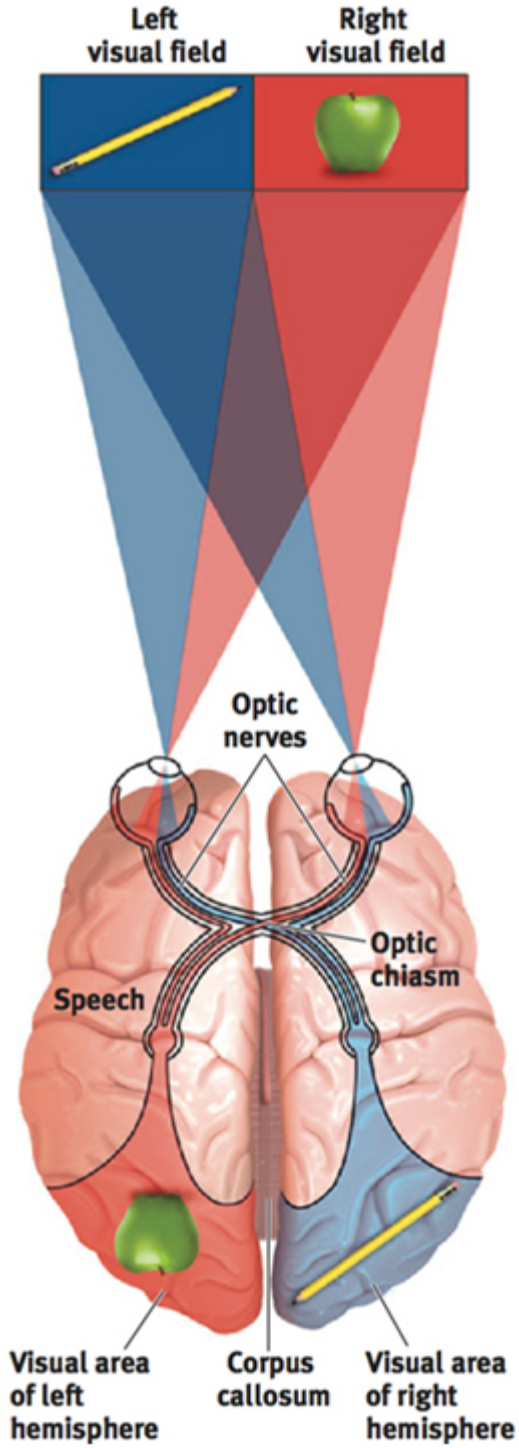
Left
visual field
Right
visual field
Optic
nerves
Optic
chiasm
Speech
Visual area
of left
hemisphere
Corpus
callosum
Visual area
of right
hemisphere

or

(c)

"Look at the dot."

(a)

(b)

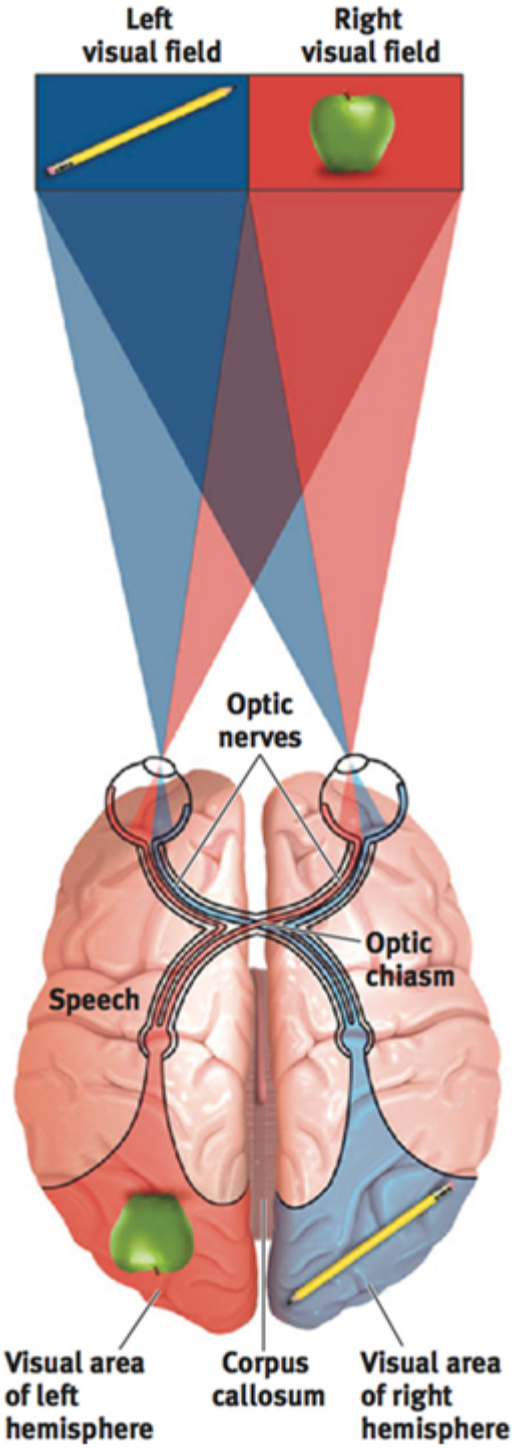

or

(c)



"Look at the dot."

(a)

Two words separated by a dot are momentarily projected.

(b)

or

(c)

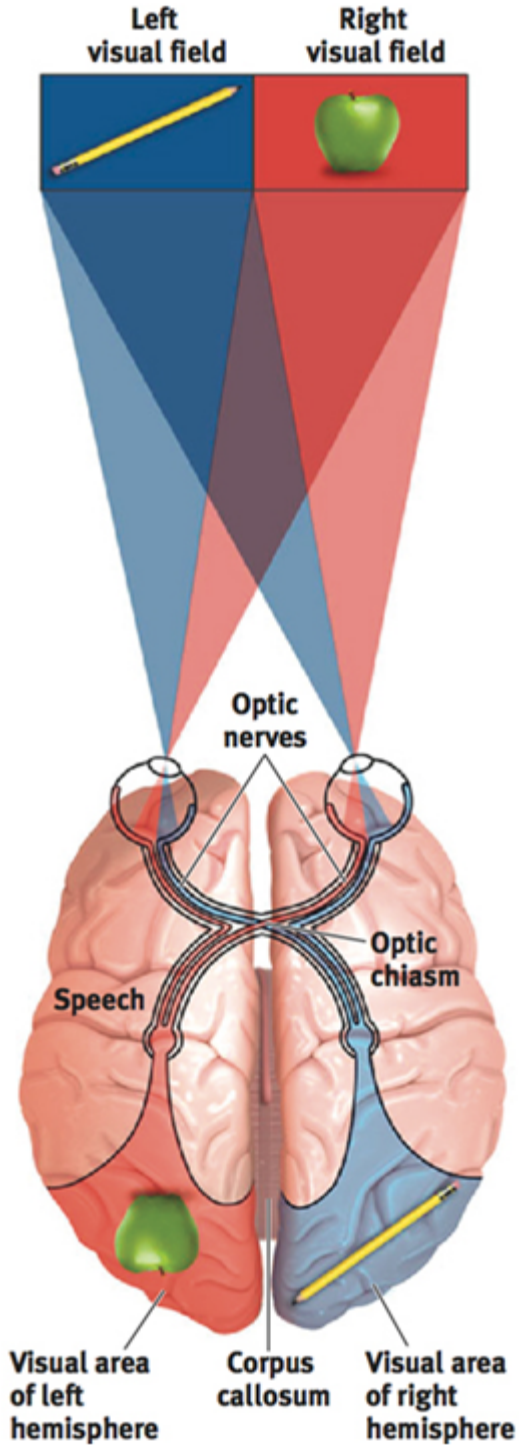

"Look at the dot."

(a)

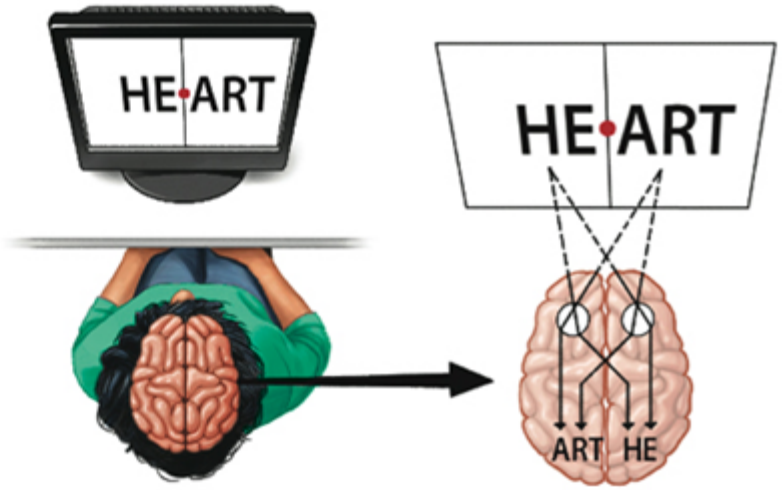

Two words separated by a dot are momentarily projected.

(b)

or

(c)

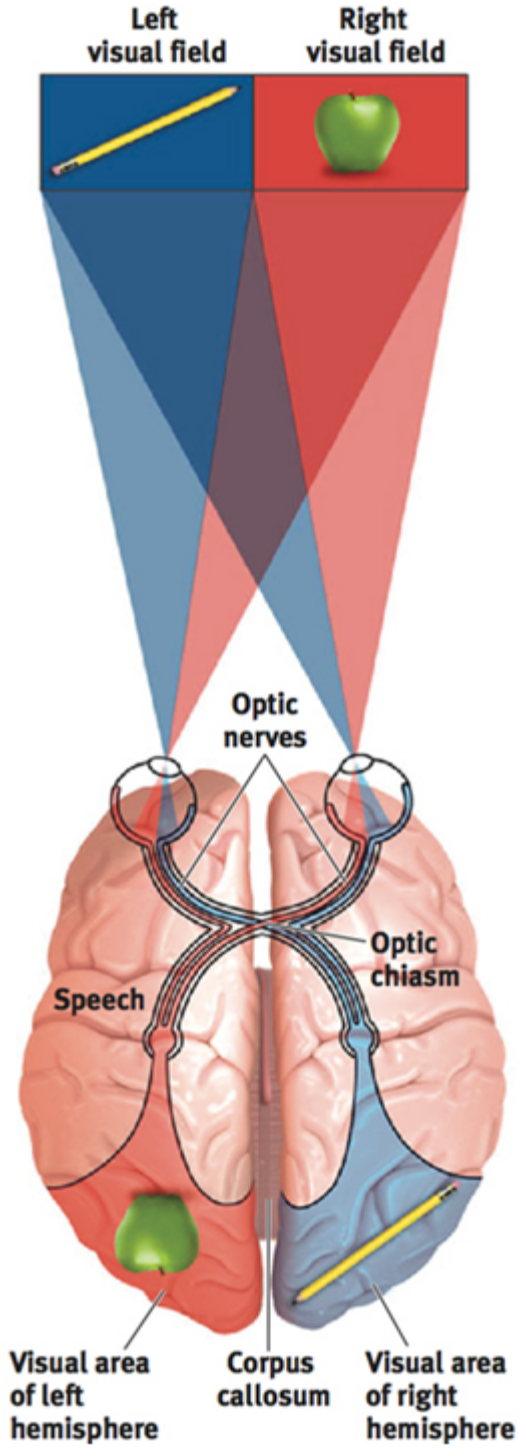

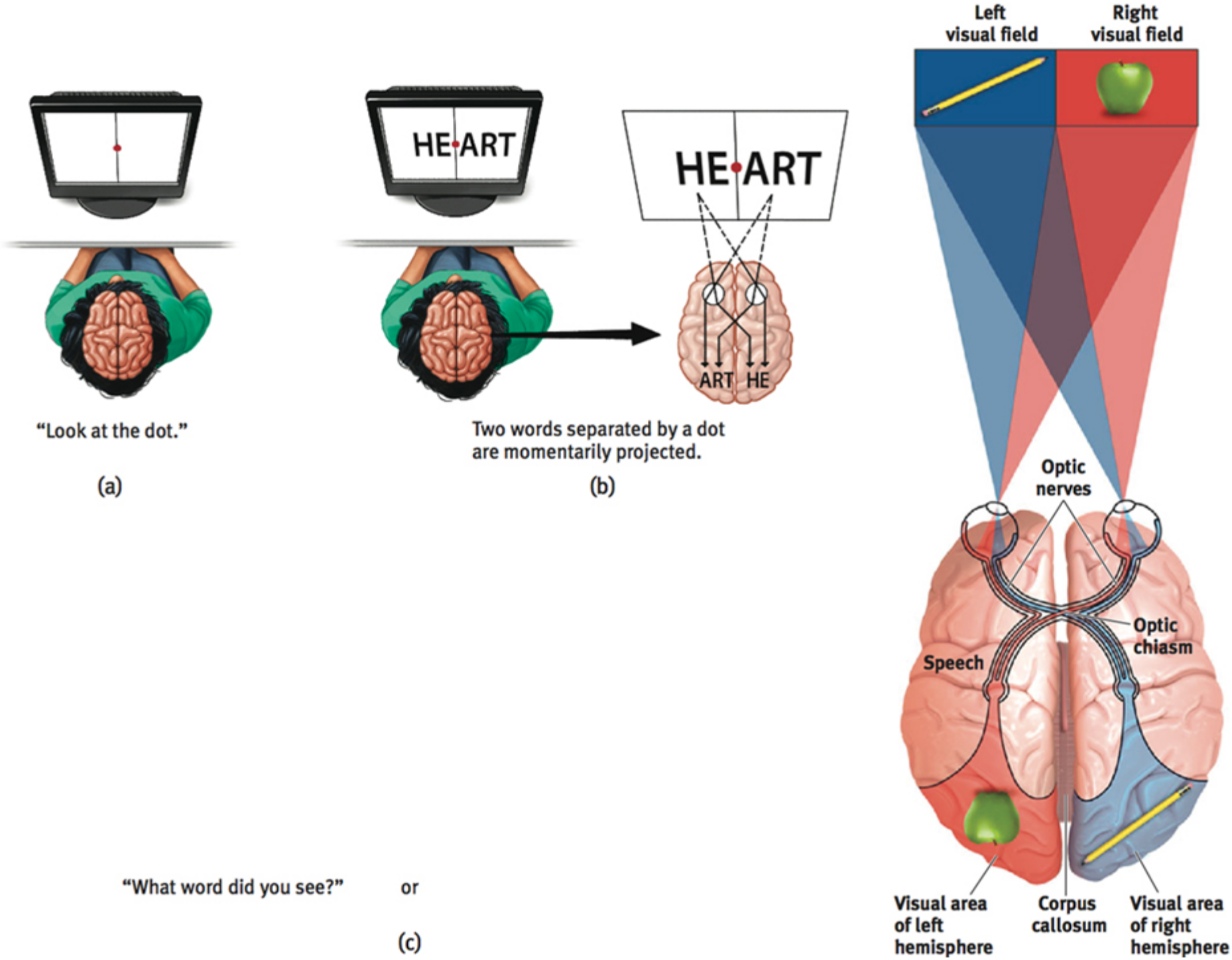

"Look at the dot."

(a)

Two words separated by a dot are momentarily projected.

(b)

"What word did you see?" or

(c)

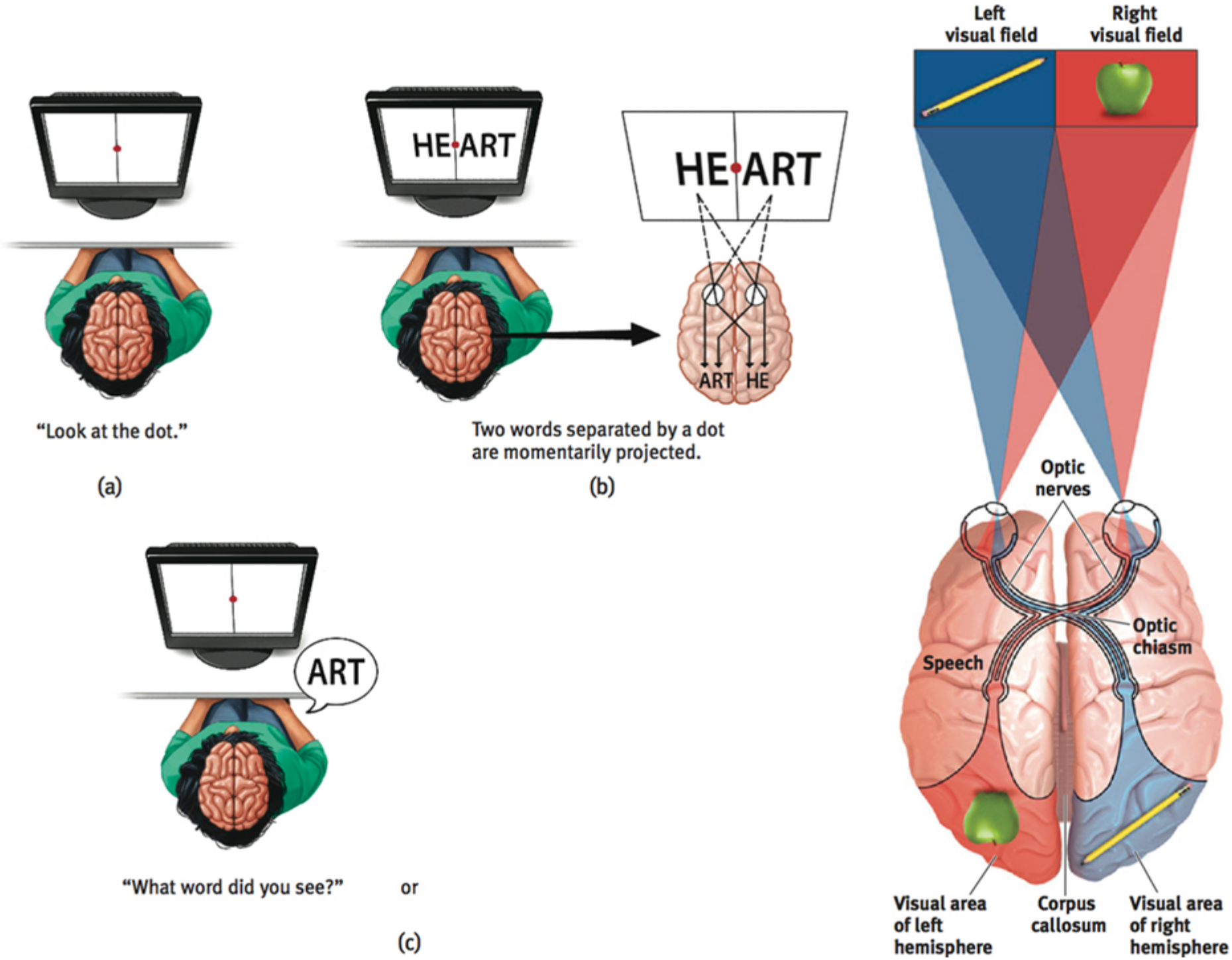
HE ART
HE ART
ART HE
"Look at the dot."
(a)
Two words separated by a dot are momentarily projected.
(b)
ART
"What word did you see?"
or
(c)
Left visual field
Right visual field
Optic nerves
Optic chiasm
Speech
Visual area of left hemisphere
Corpus callosum
Visual area of right hemisphere

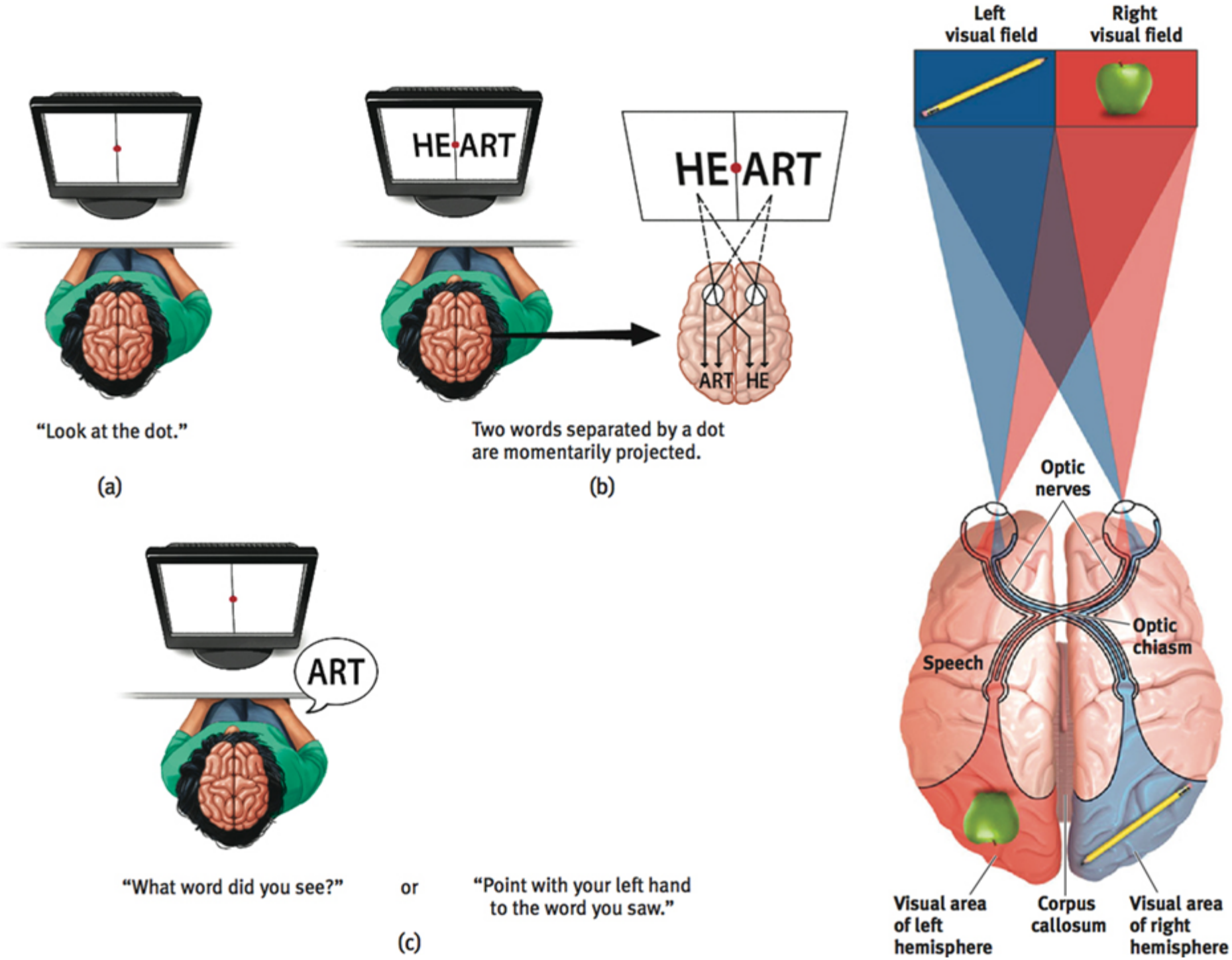
HE ART
HE ART
ART HE
"Look at the dot."
(a)
Two words separated by a dot are momentarily projected.
(b)
ART
"What word did you see?"
or
"Point with your left hand to the word you saw."
(c)
Left visual field
Right visual field
Optic nerves
Optic chiasm
Speech
Visual area of left hemisphere
Corpus callosum
Visual area of right hemisphere

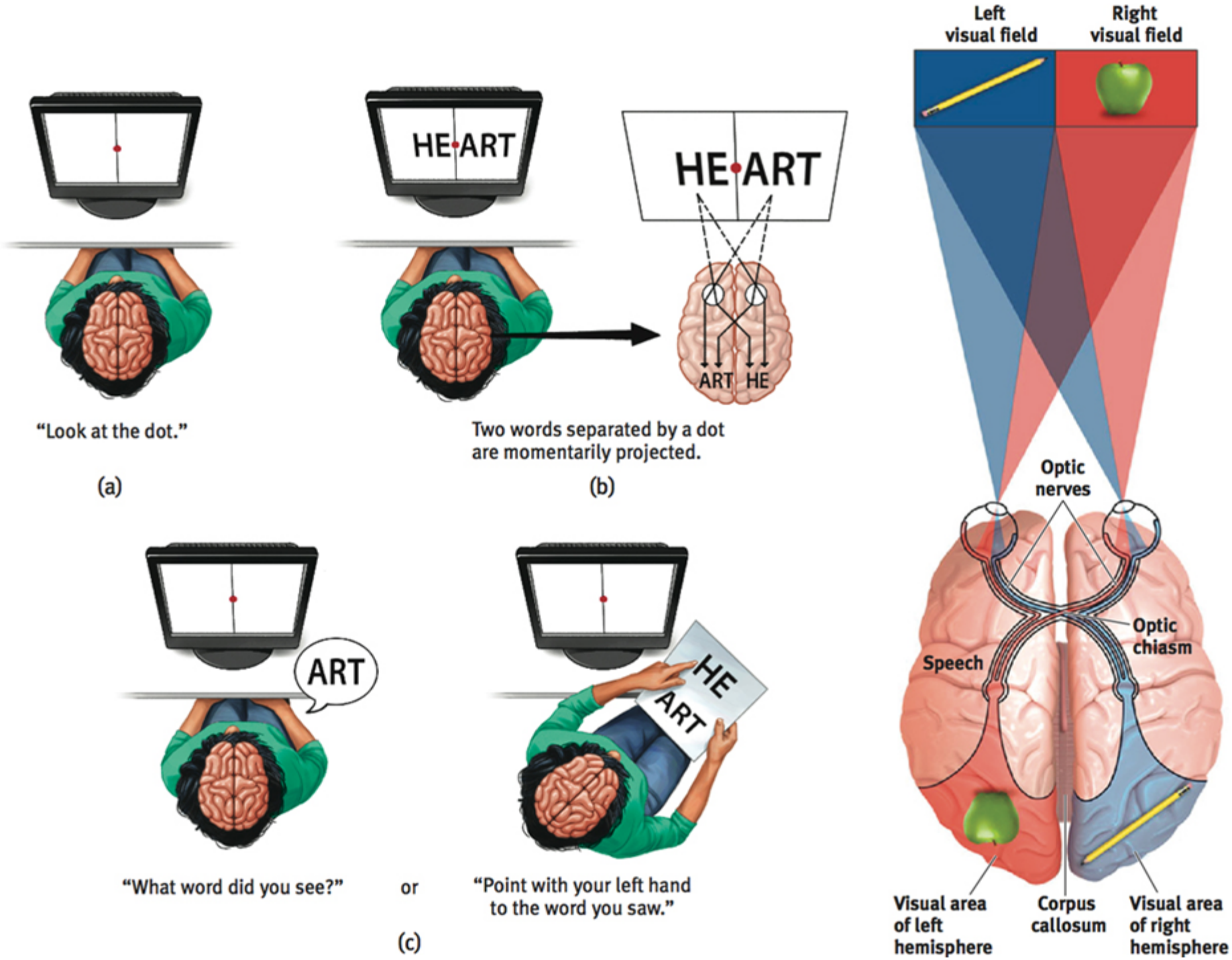
HE ART
HE ART
ART HE
"Look at the dot."
(a)
Two words separated by a dot
are momentarily projected.
(b)
ART
HE
ART
"What word did you see?"
or
"Point with your left hand
to the word you saw."
(c)
Left
visual field
Right
visual field
Optic
nerves
Optic
chiasm
Speech
Visual area
of left
hemisphere
Corpus
callosum
Visual area
of right
hemisphere

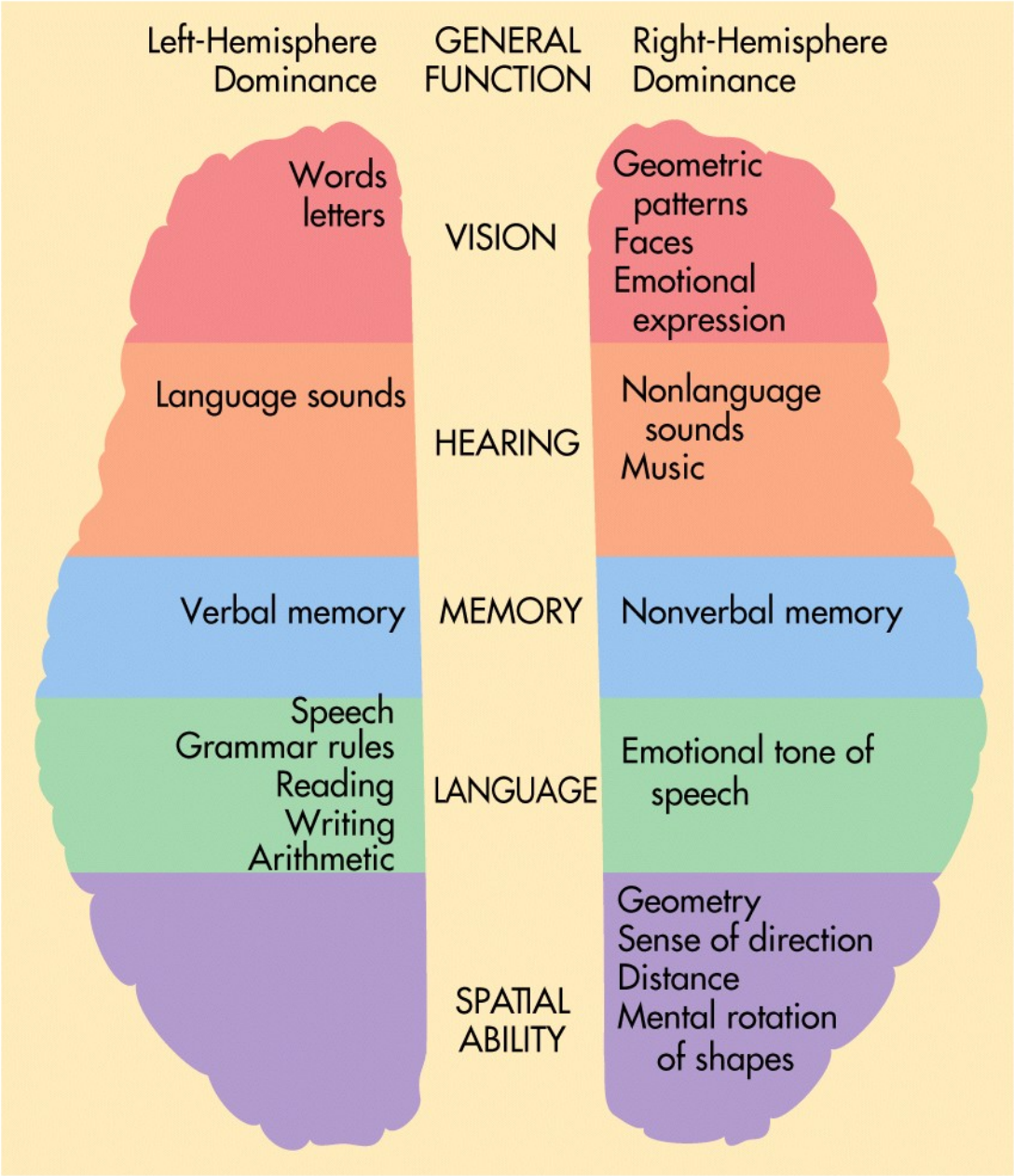
Left-Hemisphere Dominance
GENERAL FUNCTION
Right-Hemisphere Dominance
Words letters
VISION
Geometric patterns
Faces
Emotional expression
Language sounds
HEARING
Nonlanguage sounds
Music
Verbal memory
MEMORY
Nonverbal memory
Speech
Grammar rules
Reading
Writing
Arithmetic
LANGUAGE
Emotional tone of speech
SPATIAL ABILITY
Geometry
Sense of direction
Distance
Mental rotation of shapes

Right-Left Differences in the Intact Brain

Right-Left Brain Differences

- Hemispheric Specialization
  - Perceptual tasks
  - Language
  - Sense of self

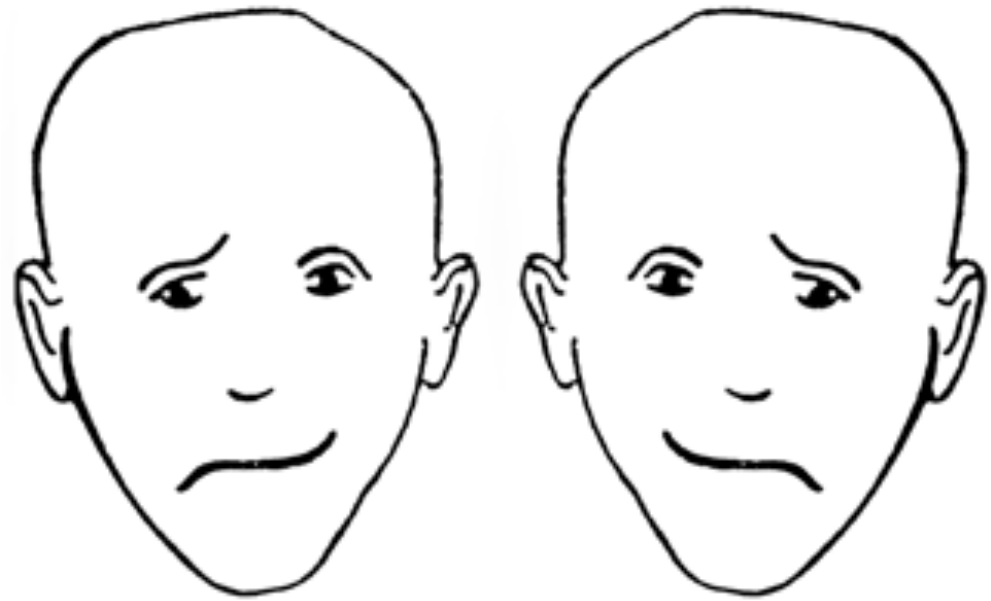

Non-Split Brains

People with intact brains also show left-right hemispheric differences in mental abilities.

A number of brain scan studies show normal individuals engage their right brain when completing a perceptual task and their left brain when carrying out a linguistic task.

Brain Organization & Handedness

Is handedness inherited? Yes. Archival and historic studies, as well as modern medical studies, show that the right hand is preferred. This suggests genes and/or prenatal factors influence handedness.

Is it All right to be Left Handed?

The percentage of left-handed individuals decreases sharply in samples of older people.

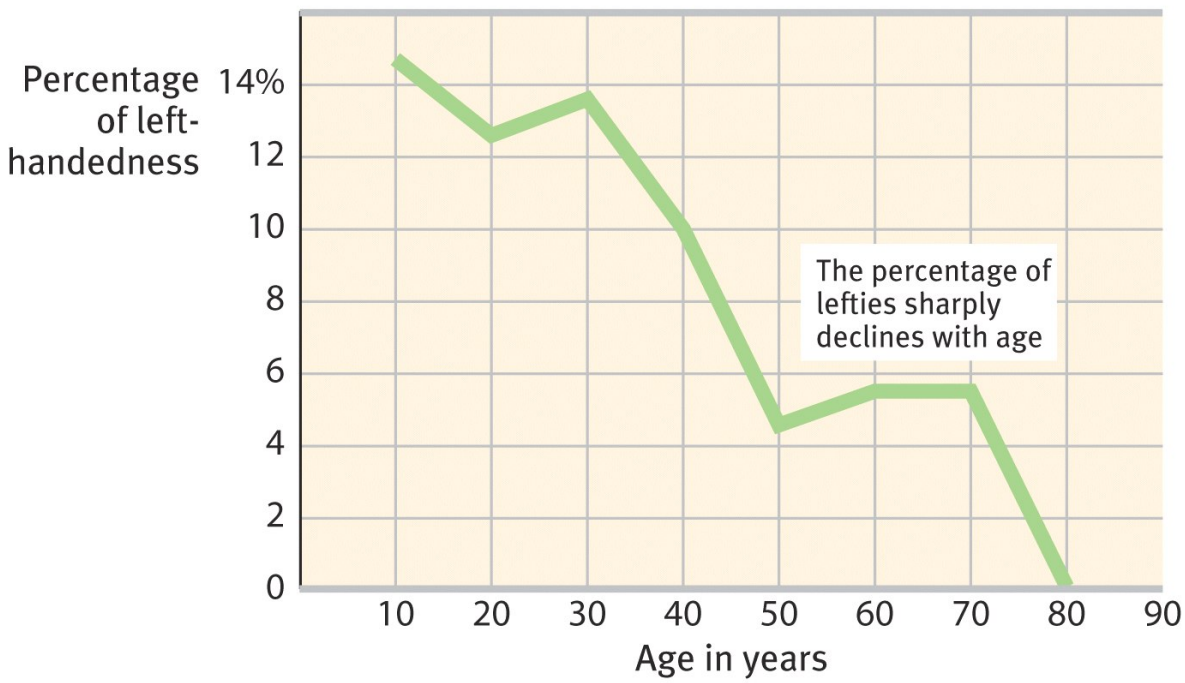

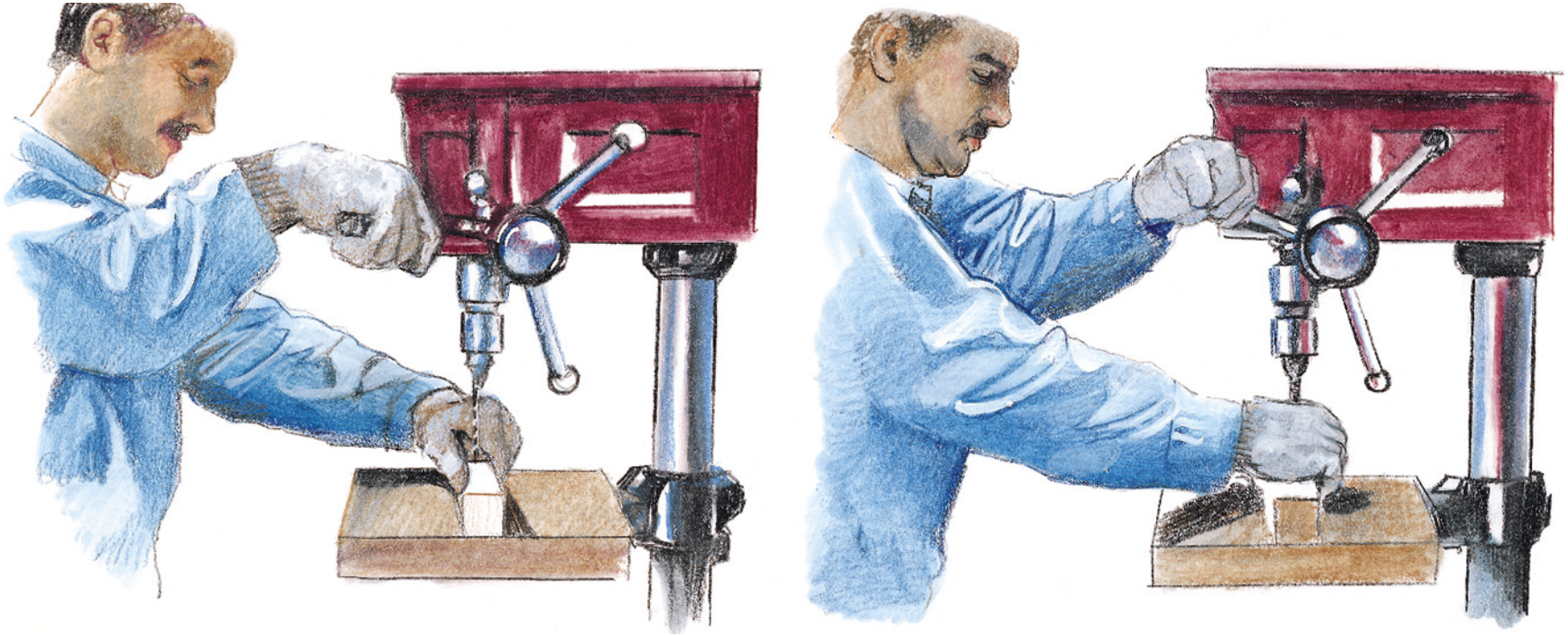

Figure 2.40 The southpaw's hazardous life
Myers: Psychology, Eighth Edition

The Brain and Consciousness

Introduction

- Consciousness

Cognitive Neuroscience

- Cognitive neuroscience

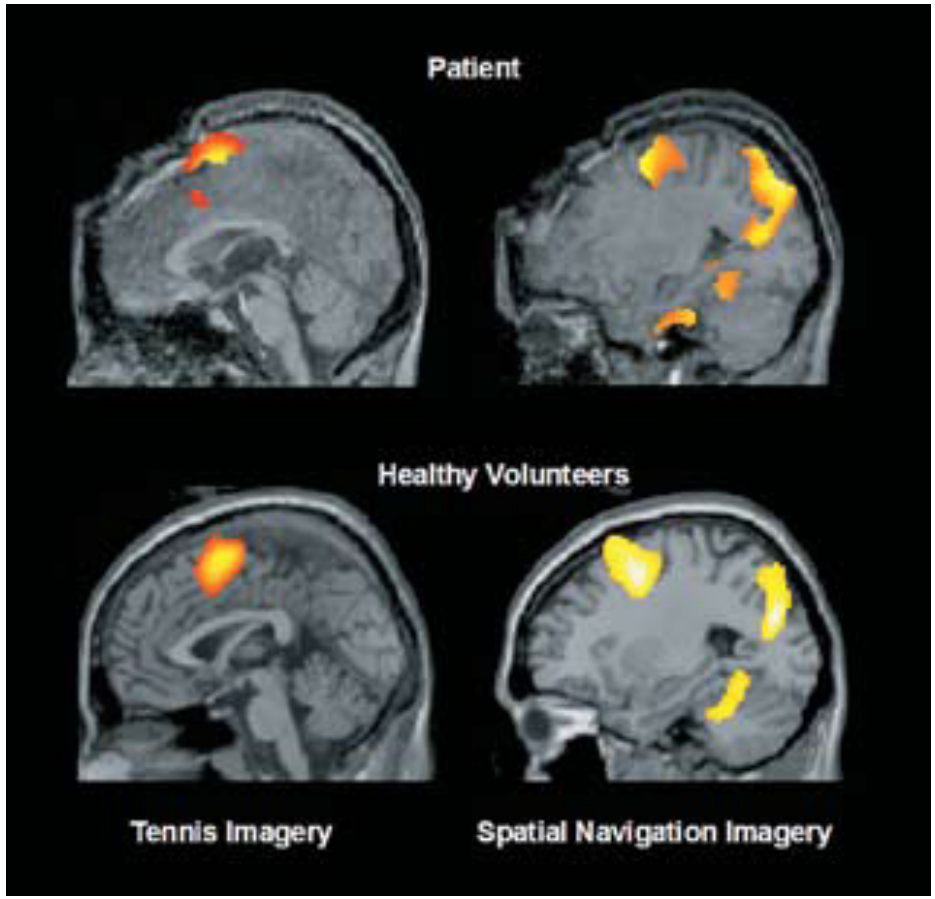

Dual Processing

- Dual Processing
  - Priming
  - Conscious left brain
  - Intuitive right brain

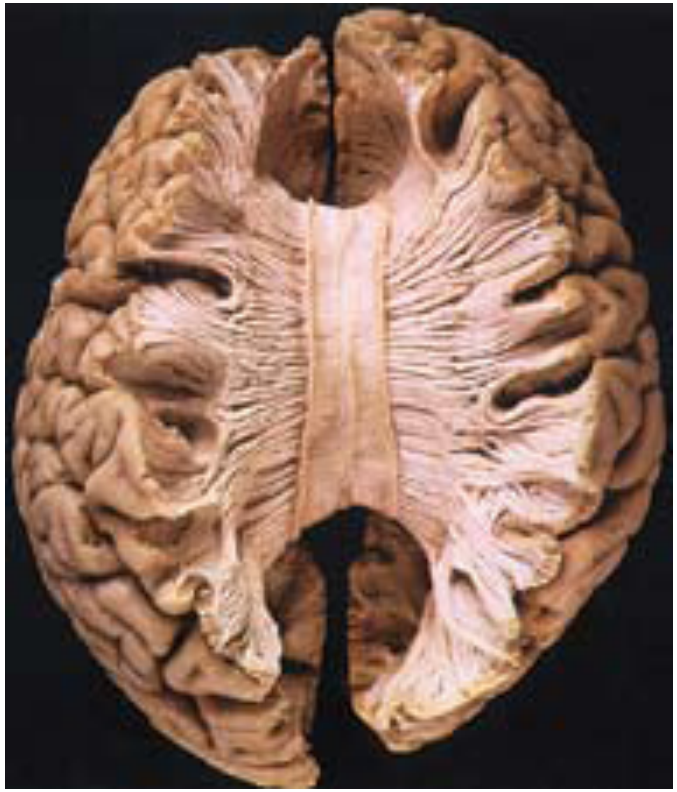

The Two-Track Mind

- Two-Track Mind
  - Visual perception track
  - Visual action track

The End